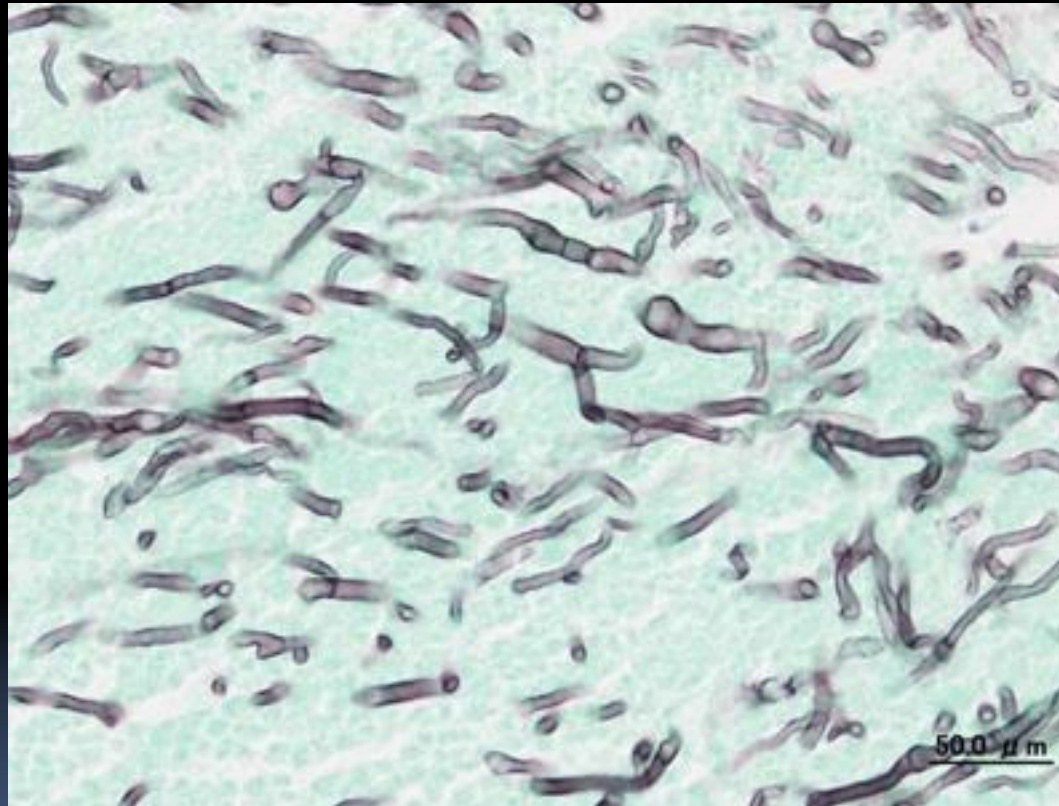


Diagnosis



Grocott's methenamine silver stain shows septate hyphae with acute angle branching characteristic of *aspergillus fumigatus*.

Diagnosis

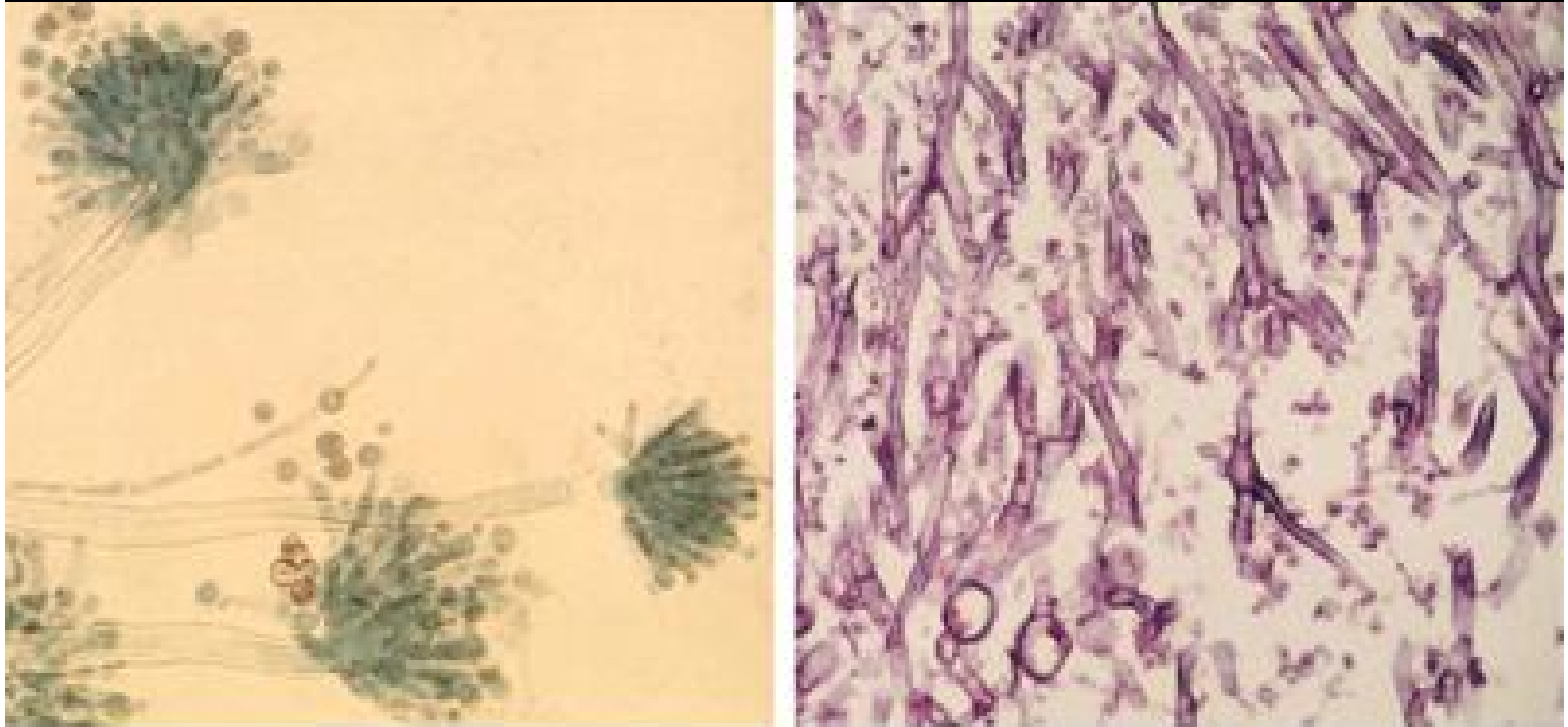


Figure 1. Microscopic features of *A. fumigatus*. **(a)** High-power photomicrograph demonstrates conidiophores with the characteristic head appearance and minute spores. **(b)** Medium-power photomicrograph shows septate hyphae branching at an angle of approximately 45° .

Diagnosis

- **Lung biopsy** : tissue from central and peripheral areas of affected lung
- **Thoracoscopic biopsy** :
not systematically studied in children

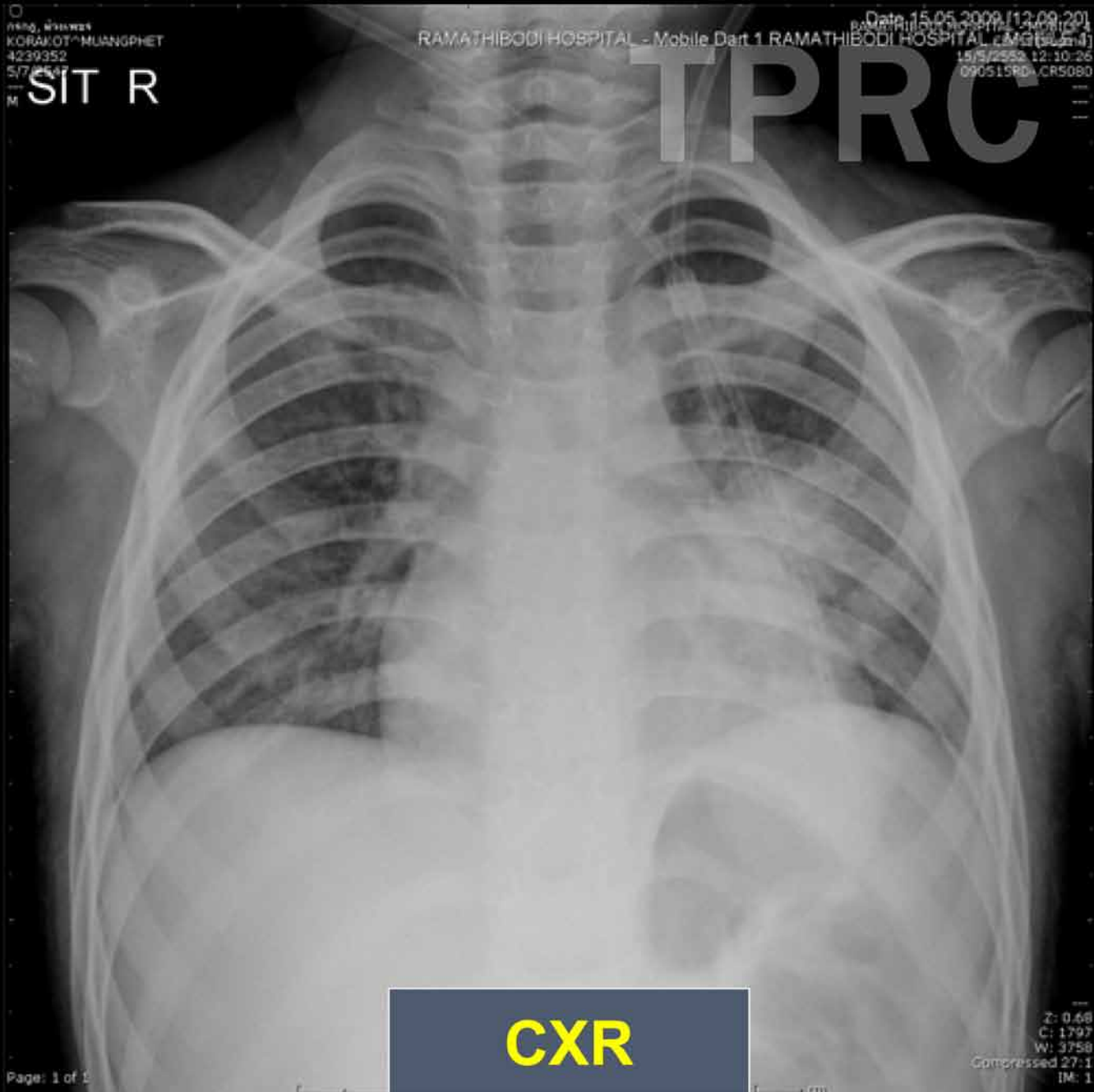
Diagnosis

- **Radiographic** : variable
- **Plain chest Radiographs** : non specific finding
 - Segmental consolidation
 - multilobar consolidation
 - Perihilar infiltrates
 - Pleural effusions and/or nodular lesions
 - 10 % Normal ; CT scan may show lesions in patients with normal radiographs

นาง, นิตยา
KORAKOT MUANGPHET
4239352
5/7/2547
M

RAMATHIBODI HOSPITAL - Mobile Dart 1 RAMATHIBODI HOSPITAL - Mobile Dart 1
Date: 15/05/2009 12:10:26
090515RD, CR5080

TPRC



CXR

Z: 0.68
C: 1797
W: 3758
Compressed 27:1
IM: 1