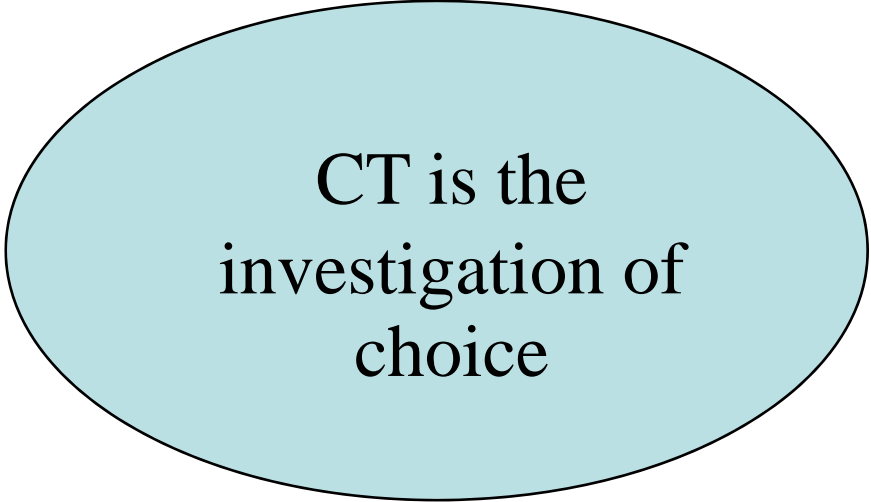
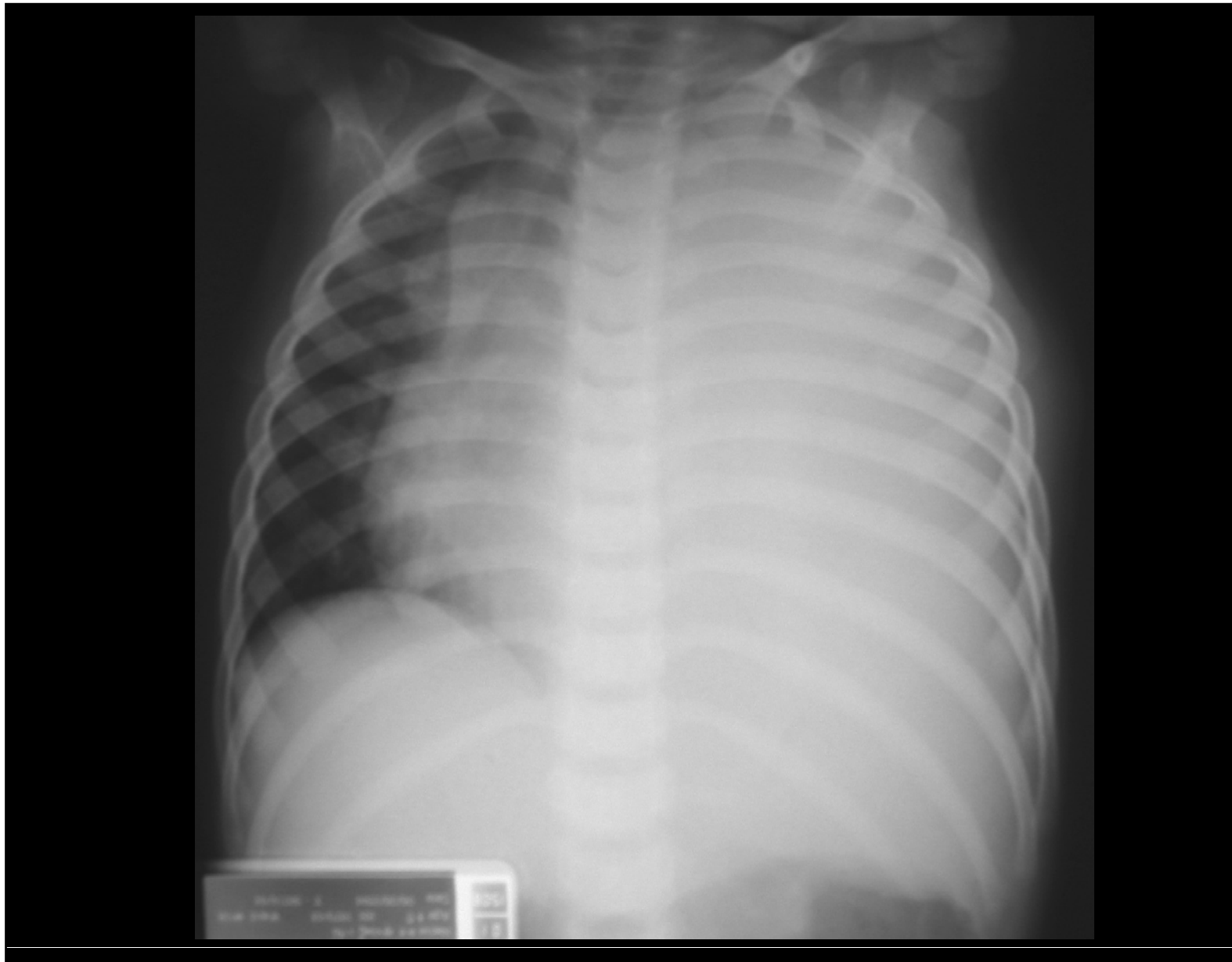


Pleural neoplasm

- Metastasis
 - *Lymphoma*
 - *Neuroblastoma*
 - *Wilms tumor*
- Mesothelioma
- Chest wall tumor involving pleura
 - *Ewing's sarcoma / PNET*
 - *Sarcoma : Rhabdomyosarcoma*



CT is the
investigation of
choice



Boy 8 years, Past history of Wilms tumor