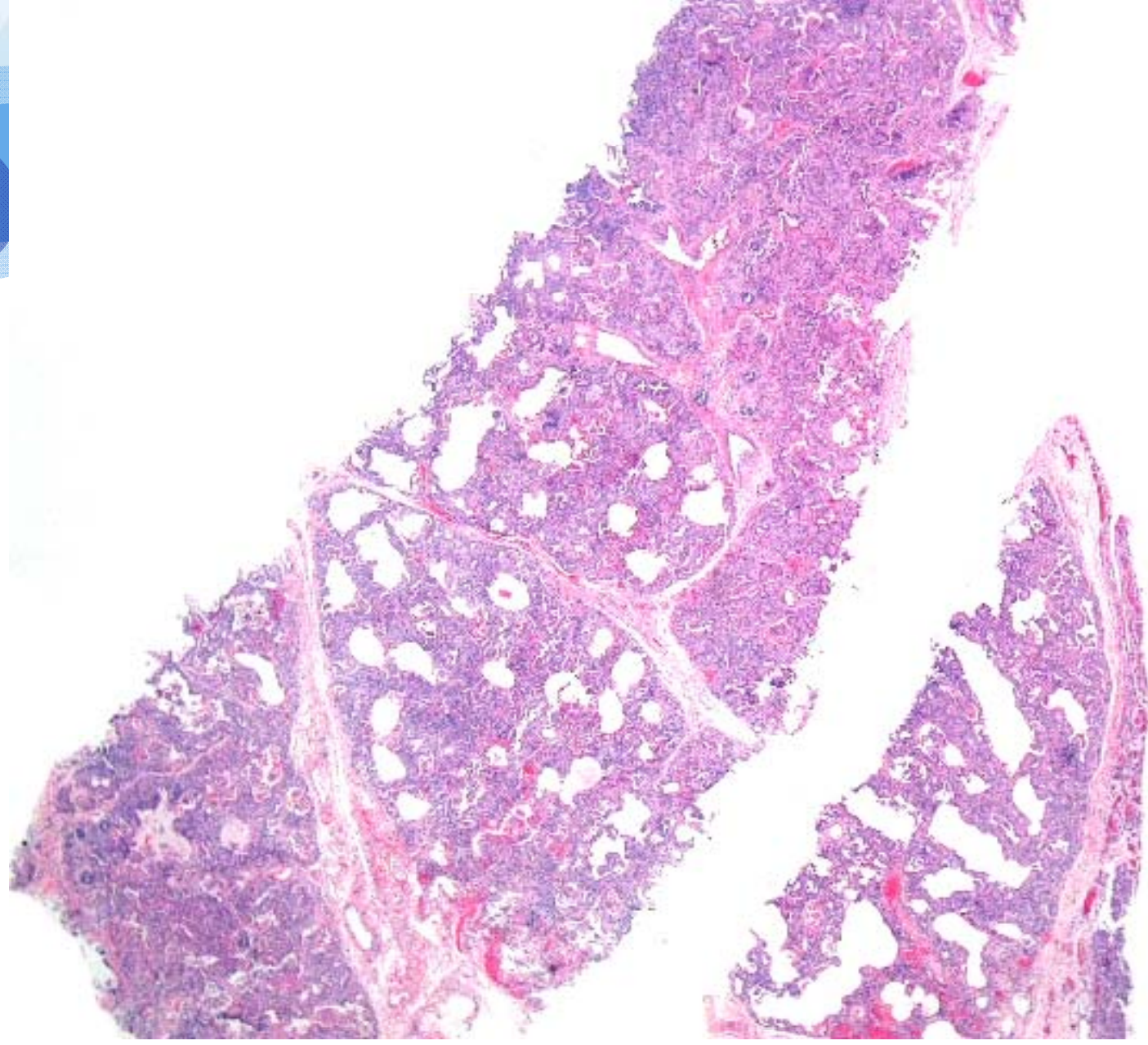


## Case 1 HN 481-27-91

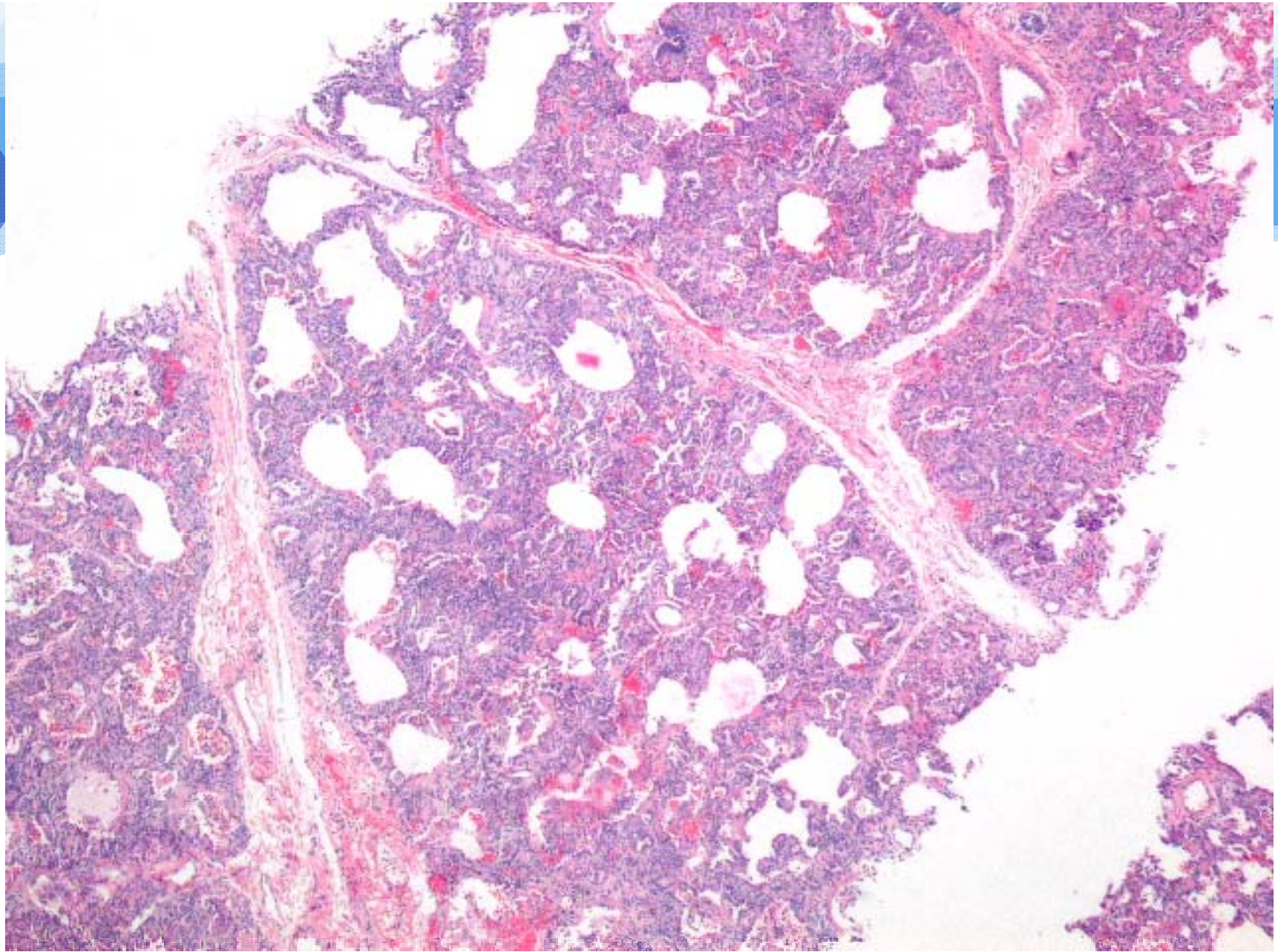
- ❖ 1. S14-15886, received 25 Jun 2014
  - A: Middle lobe of the right lung (RML)
  - B: Lower lobe of the right lung (RLL)

# Microscopic morphology





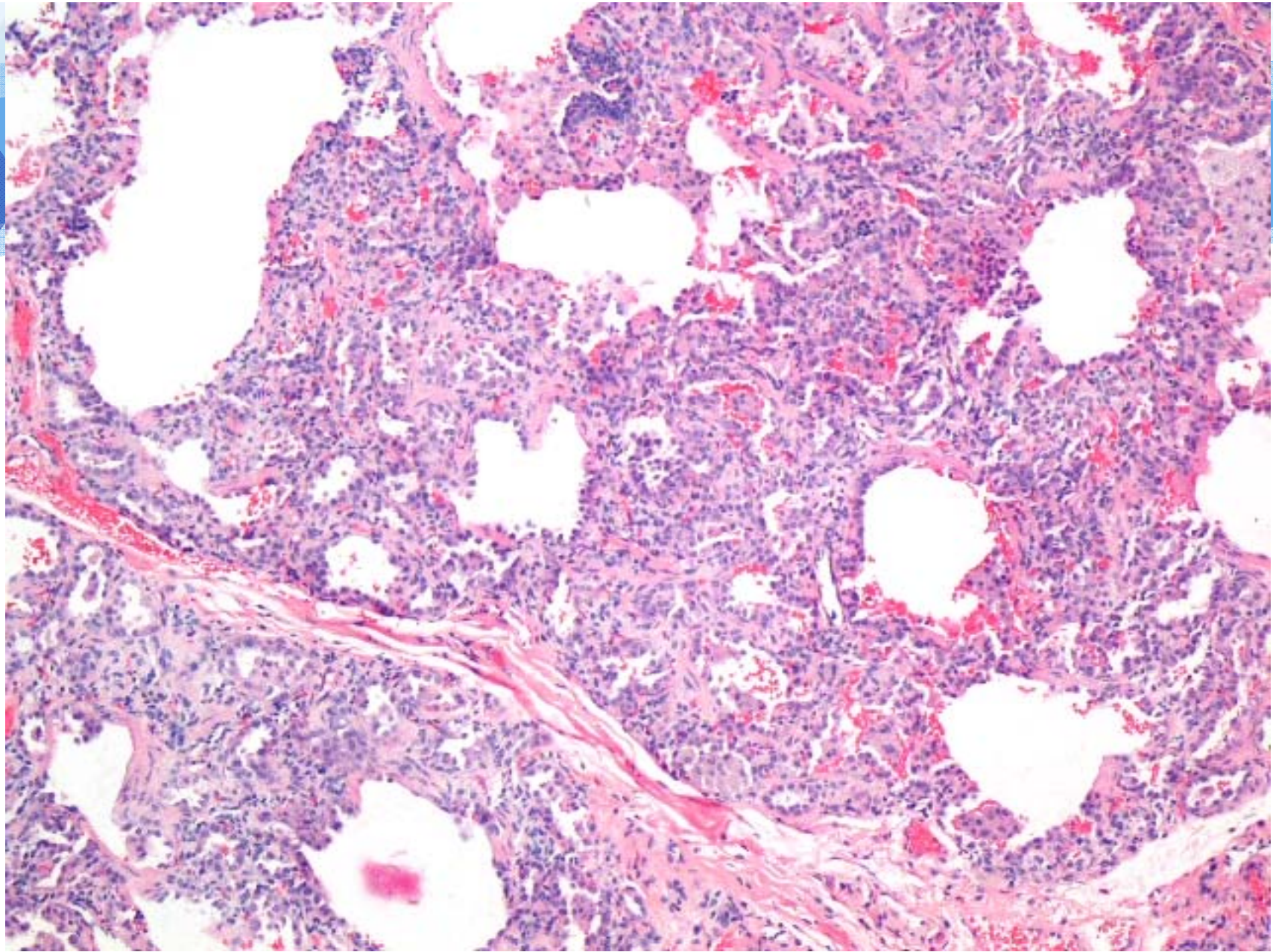
# Microscopic morphology



**Markedly alveolar septal thickening**



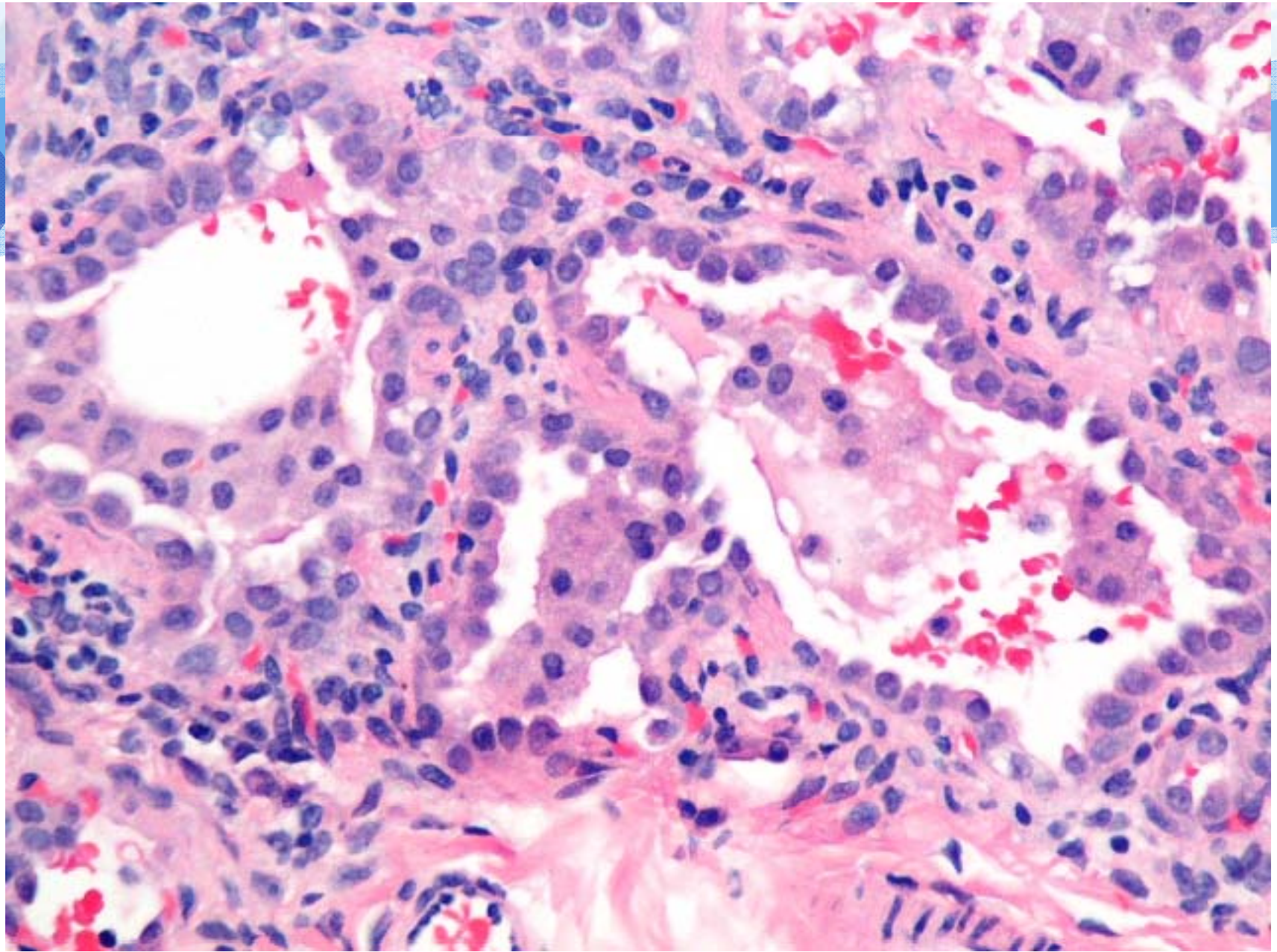
# Microscopic morphology



**Markedly alveolar septal thickening**



# Microscopic morphology



Type II pneumocyte hyperplasia