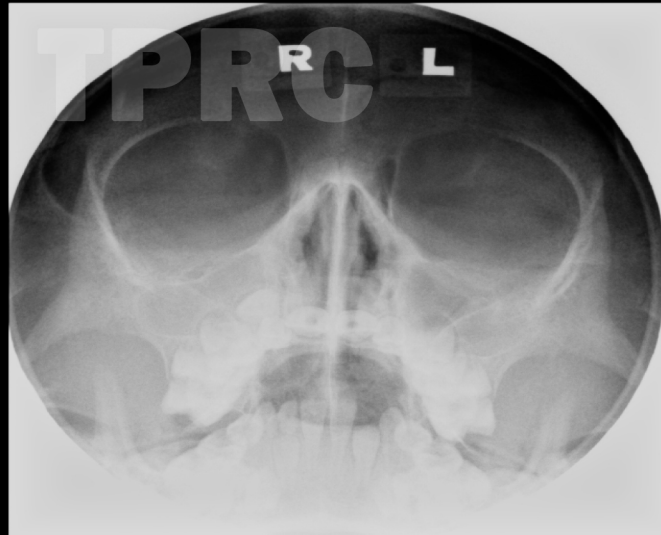


พิทักษ์, ทนพล
Phitakorn Thongplew, Boy, 7Yrs.
4044835
24/8/2543

M

RAMATHIBODI HOSPITAL (room 1,2)
HEAD, SKULL, PA
28/3/2550 13:35:13



HRCT chest 22May2007

**chronic airway disease with diffuse
bronchial wall thickening and mild
bronchiectasis of both lungs, mucus plug at
the posterior segment of RUL**

CT sinus 22May2007

- Rt. Maxillary sinusitis, infundibular pattern**
- Mild mucoperiosteal thickening of right anterior ethmoid, left maxillary and bilateral ethmoid and sphenoid sinusitis**

- **Sweat chloride test: 126 mmol/l**

Diagnosis

- Cystic fibrosis