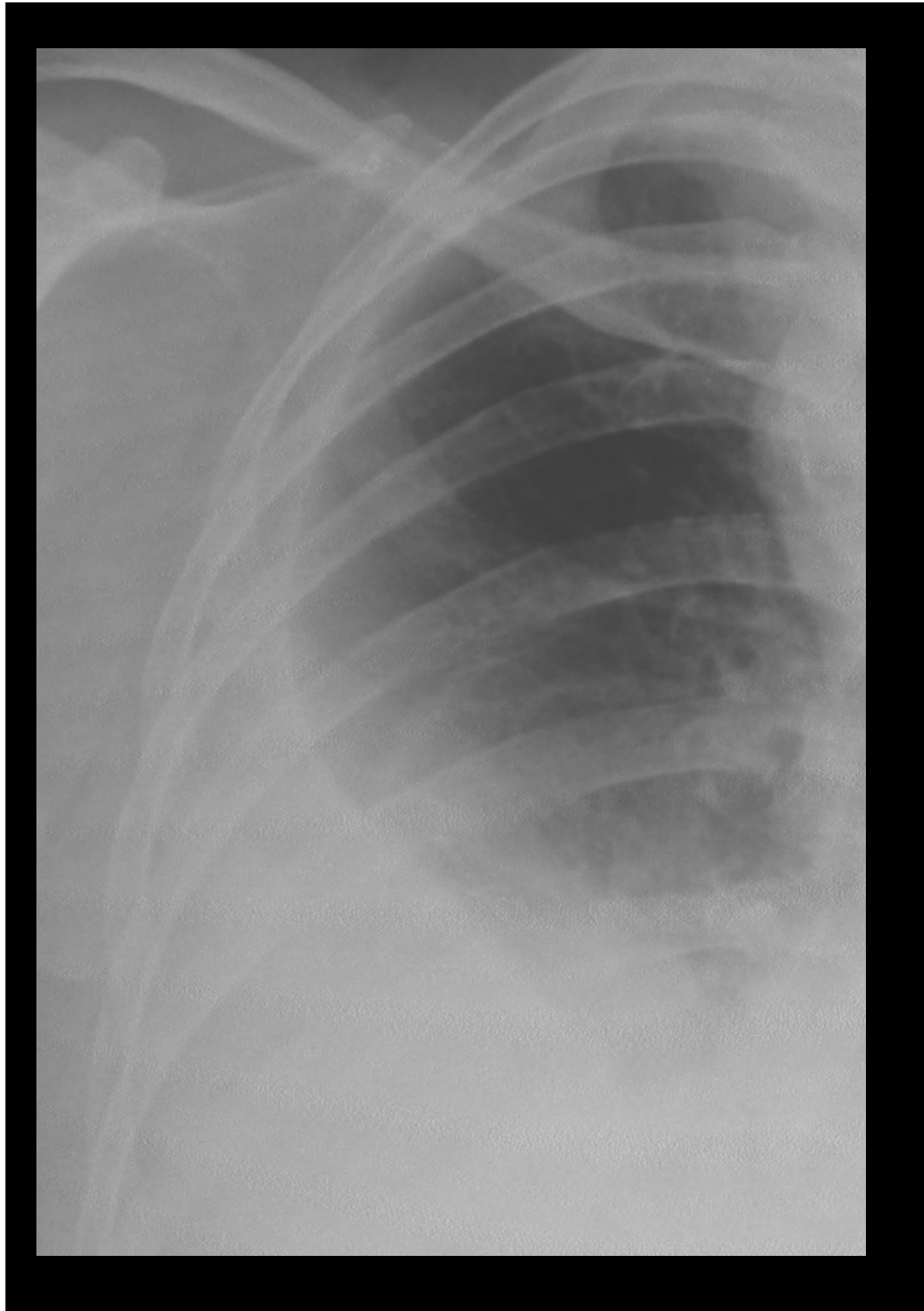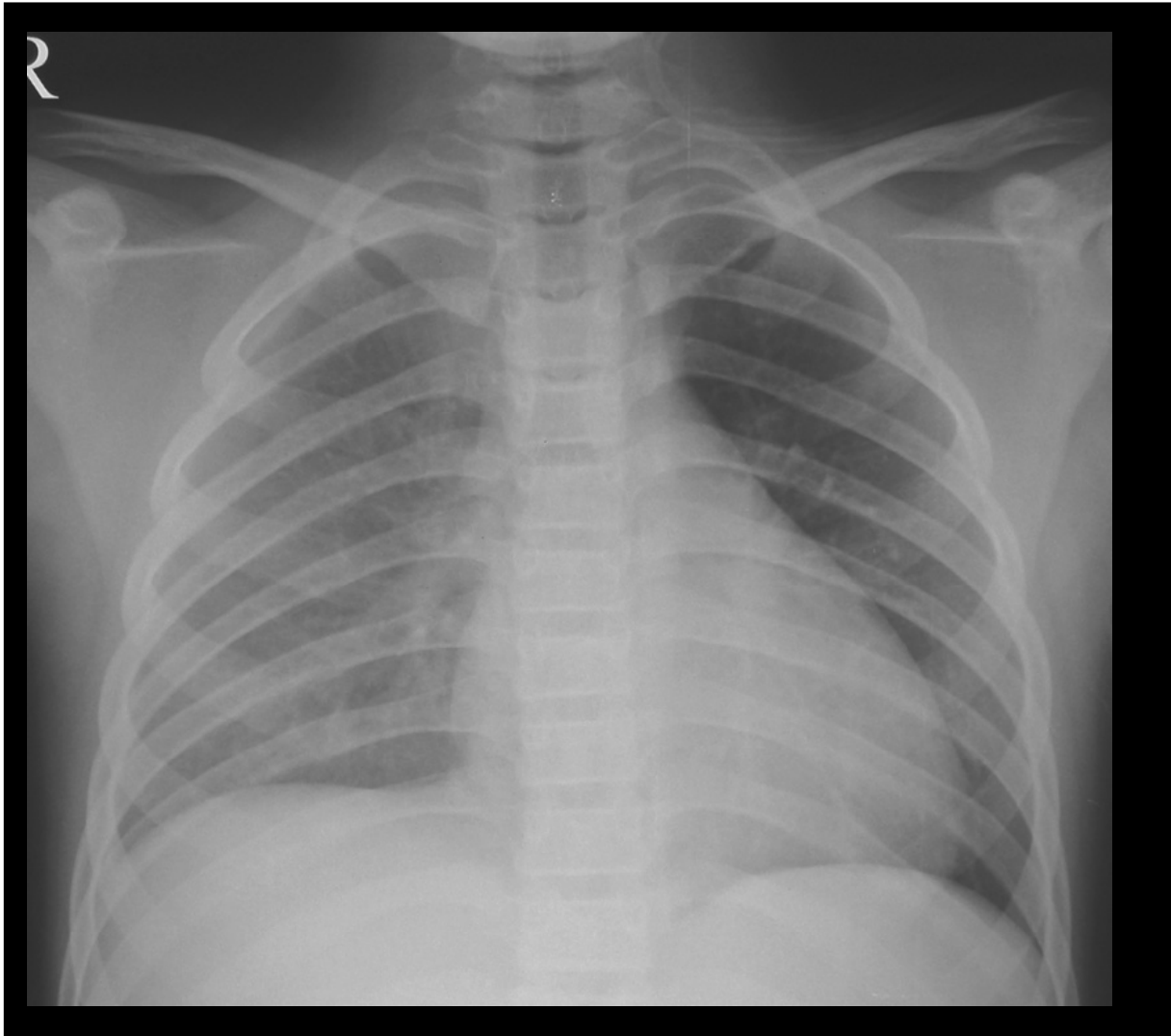


Pleural effusion

- Chest X-ray
- Upright position
- Fluid curve /
Meniscus

Adult chest upright



Pleural effusion

- Supine position
- Opaque hemithorax

Chest AP supine

Girl 8 years, DHF