

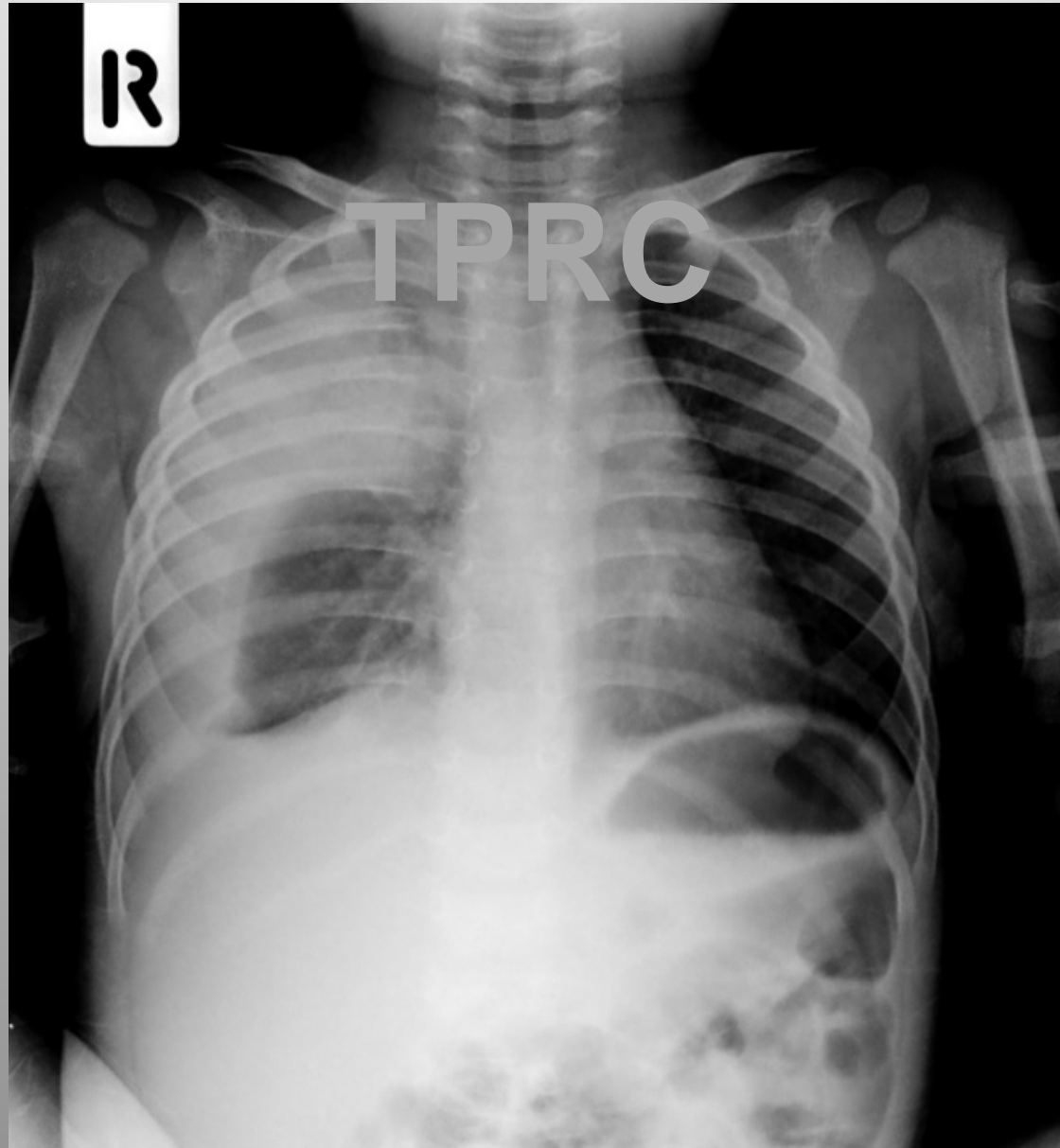
# Parapneumonic effusion: What's new?

Manutham Manavathongchai MD,MPA

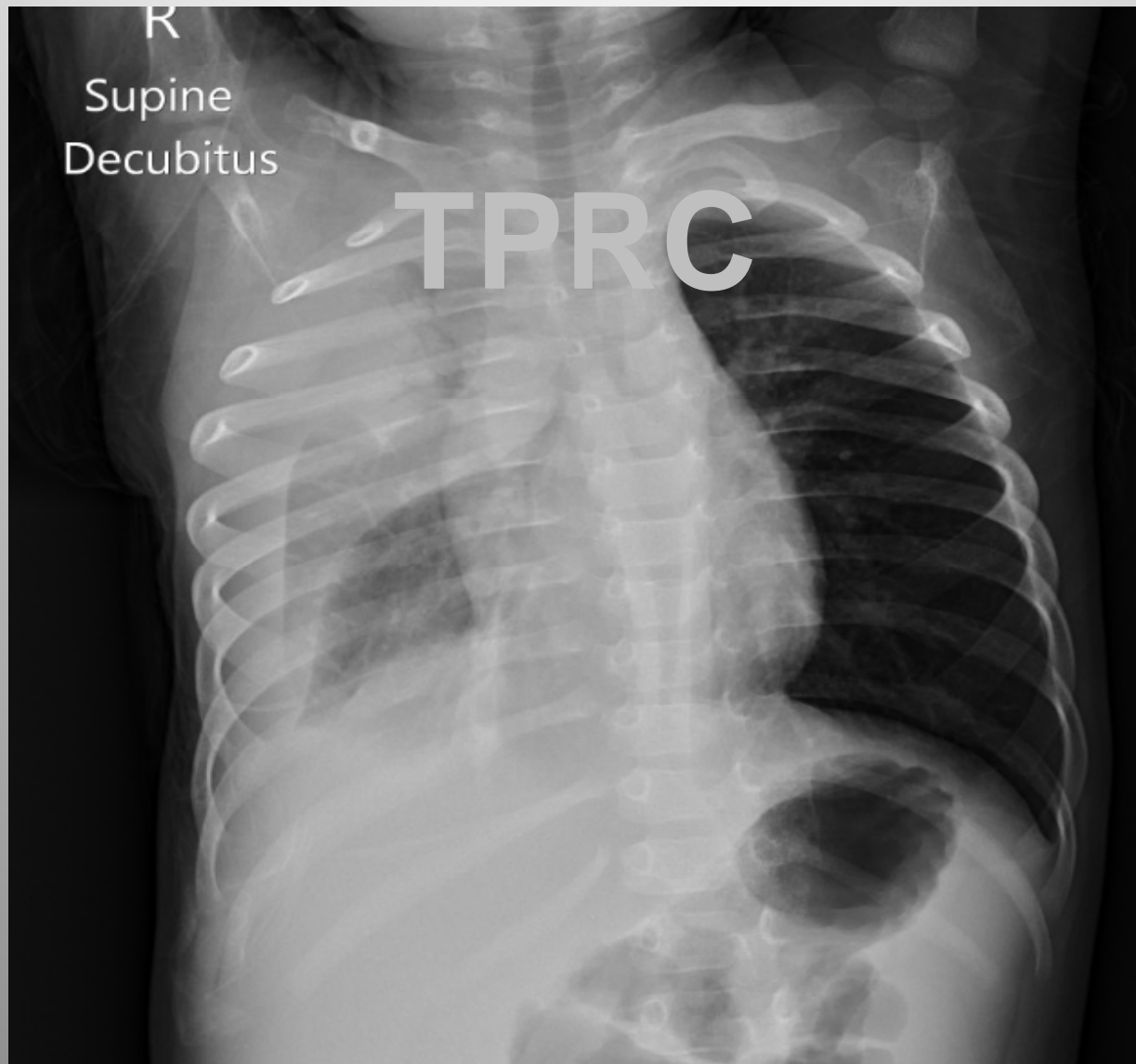
# Case

- 1 year old boy referred from private hospital
  - Fever, coughing and dyspnea 5 days
  - On Cefotaxime 2 days changed to Vancomycin + Clarythromycin D3
- PE: T=38.7, RR=60/min, PR= 150/min, BP=85/60 mmHg
  - Decreased BS right side

# Fever D5



# Fever D5 (decubitus)



# Question 1

- ควรทำ **investigation** อะไรเป็นอันดับแรก
  - A) Repeated CXR
  - B) Ultrasound chest
  - C) CT chest
  - D) Serum mycoplasma titer
  - E) Thoracentesis