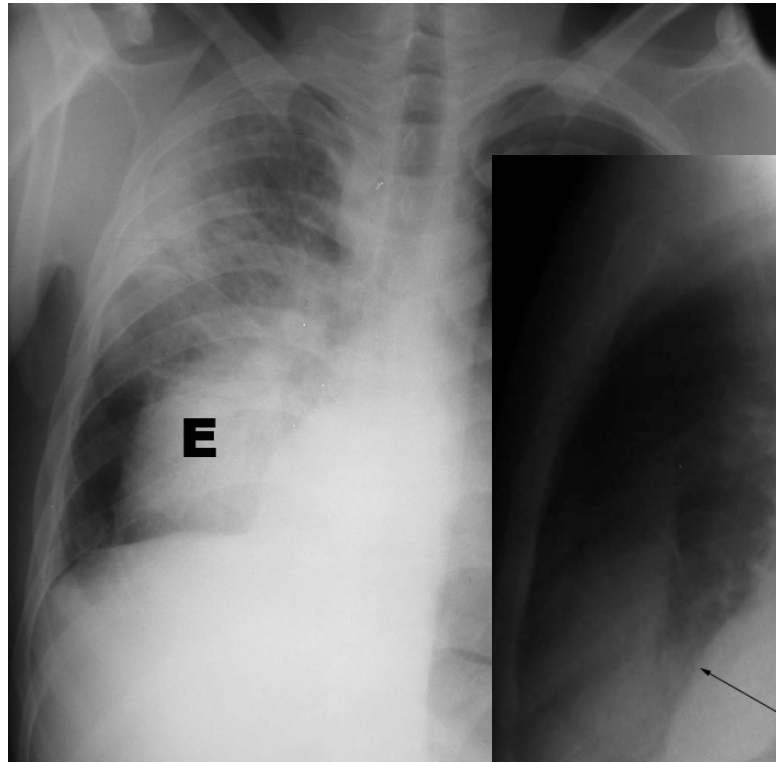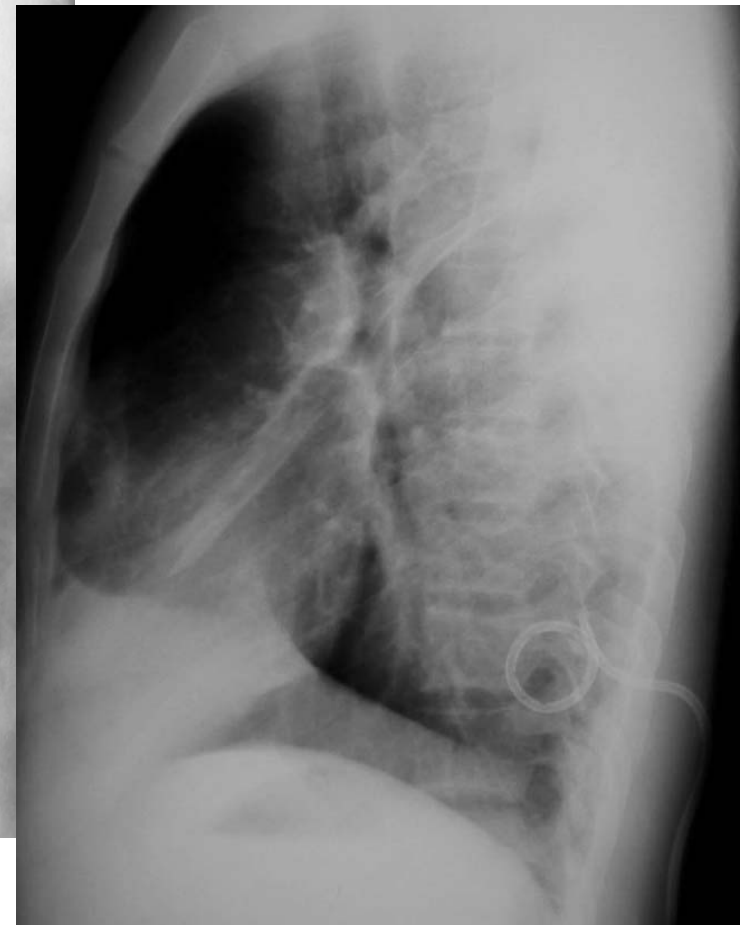
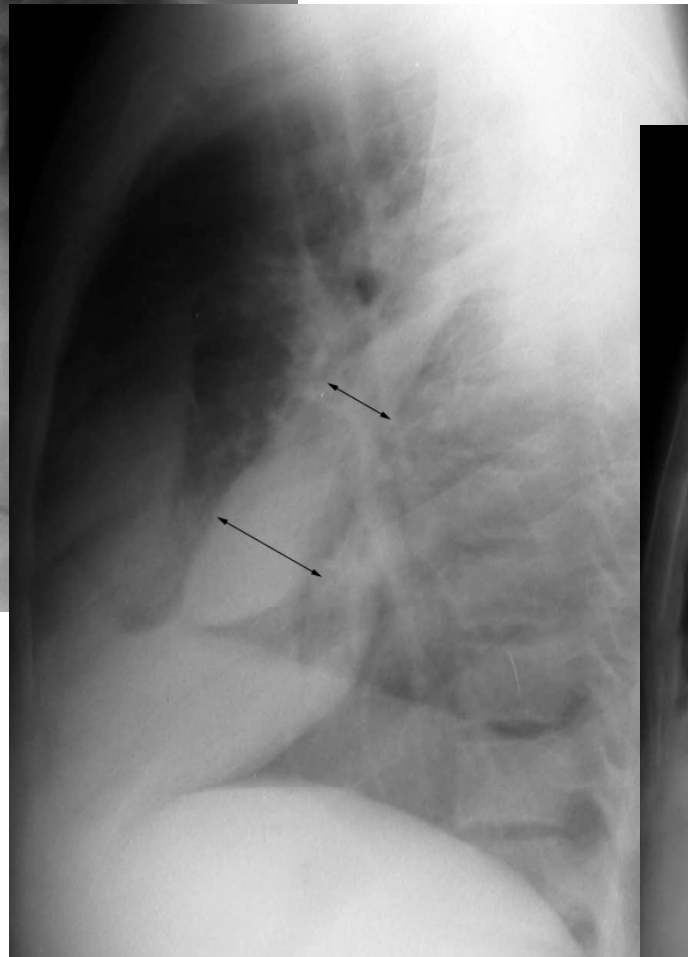
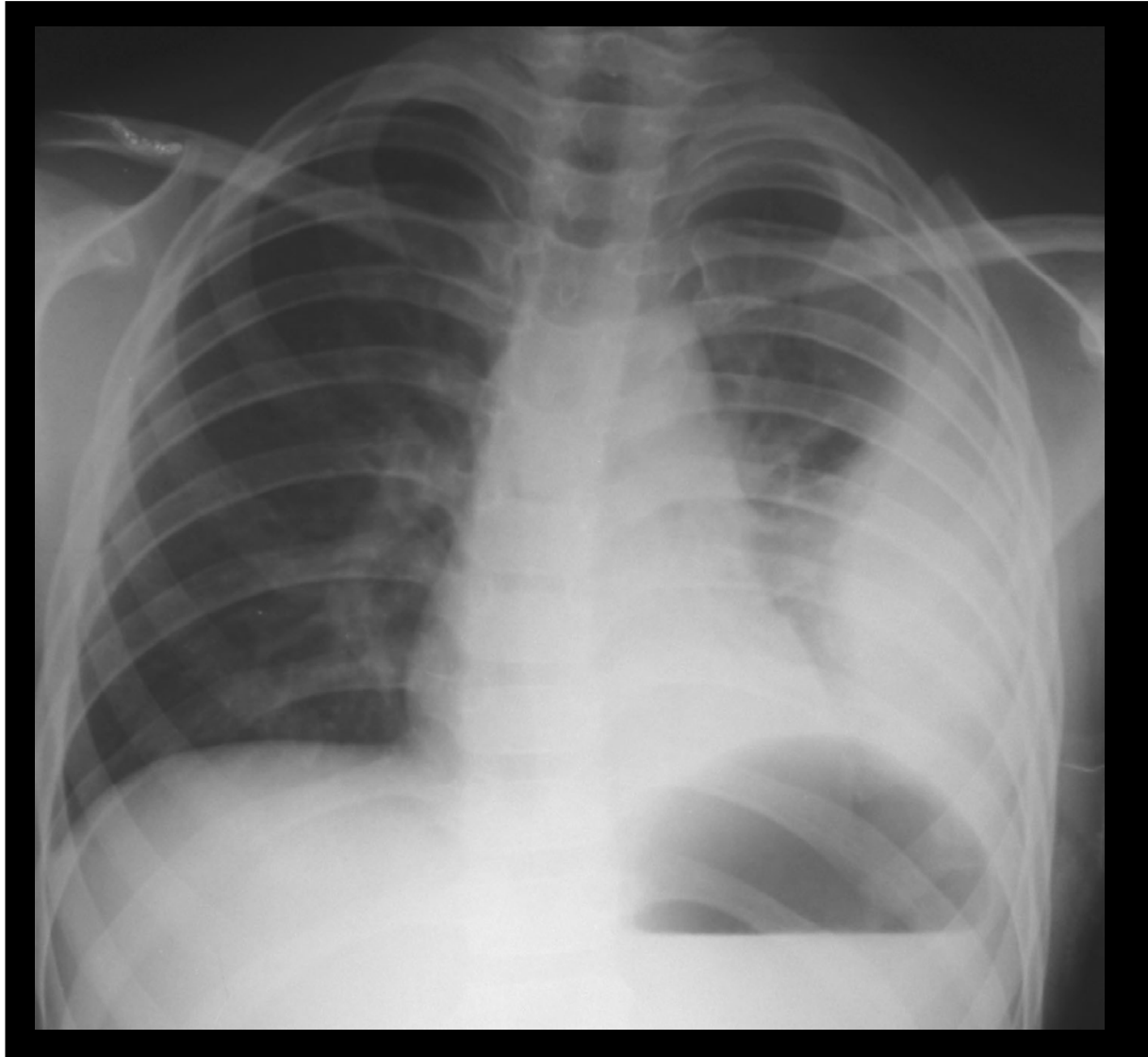


- Pleural effusion in major fissure



Chest PA upright

Pneumonia in RUL, mass like lesion in right lower chest



## **Loculated Pleural Effusion**

- Vertical lens shape
- Not change in lateral decubitus

Chest PA upright

Boy 11 years, Pneumonia in LLL

# Parapneumonic effusion & Empyema

- Stage I : **Noninfected exudative parapneumonic effusion**
  - *Simple pleural effusion*
  - *Echofree fluid from ultrasound*
  - *± pleural enhancement from CT*
- Stage II : **Fibrinopurulent**
  - *Usually loculated pleural effusion*
  - *Echogenic fluid, debris, or septation from US*
  - *Pleural enhancement on CT*
- Stage III : **Organizing empyema**
  - *Thickened pleura*