

Optimizing Newly Investigations in Pediatric Respiratory Diseases

Chest Ultrasound

ผ.ศ. พ.ญ. ปานฤทัย ตรีนวรัตน์

ภาควิชารังสีวิทยา คณะแพทยศาสตร์

จุฬาลงกรณ์มหาวิทยาลัย

Usual imaging for pediatric chest

- Chest X-ray

- CT

- (US)

- (MRI)

Which structures of the chest are suitable for ultrasound?

*** ALL, EXCEPT AERATED LUNG ***

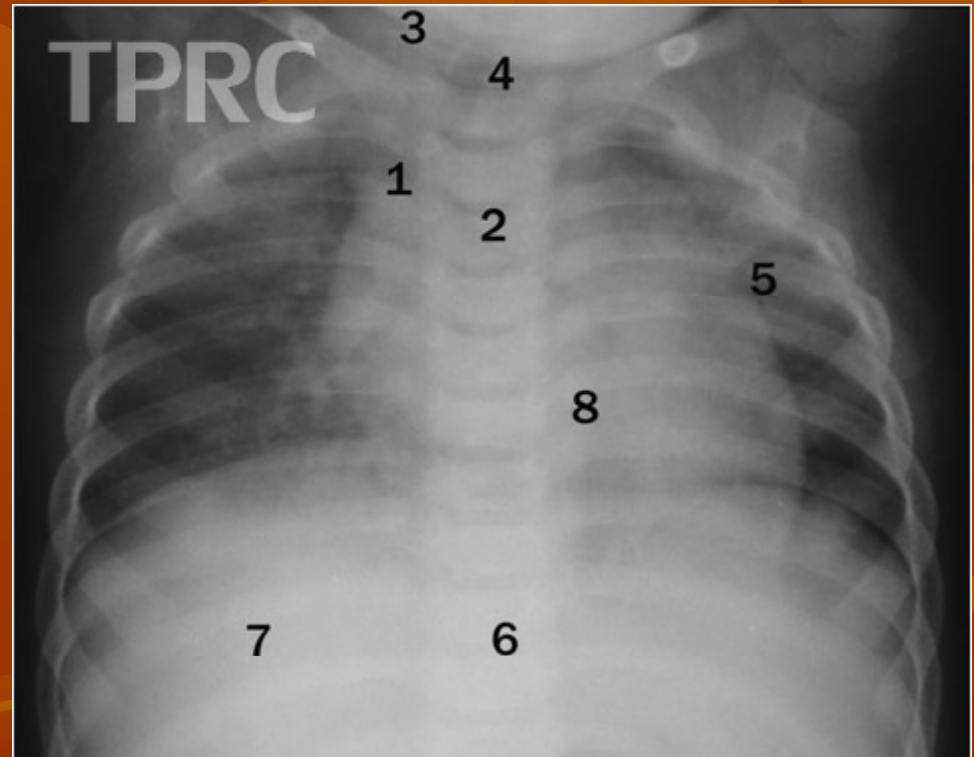
- **Chest wall**
- **Pleura & pleural space**
- **Mediastinum**
- **Nonaerated lung**
- **Diaphragm**

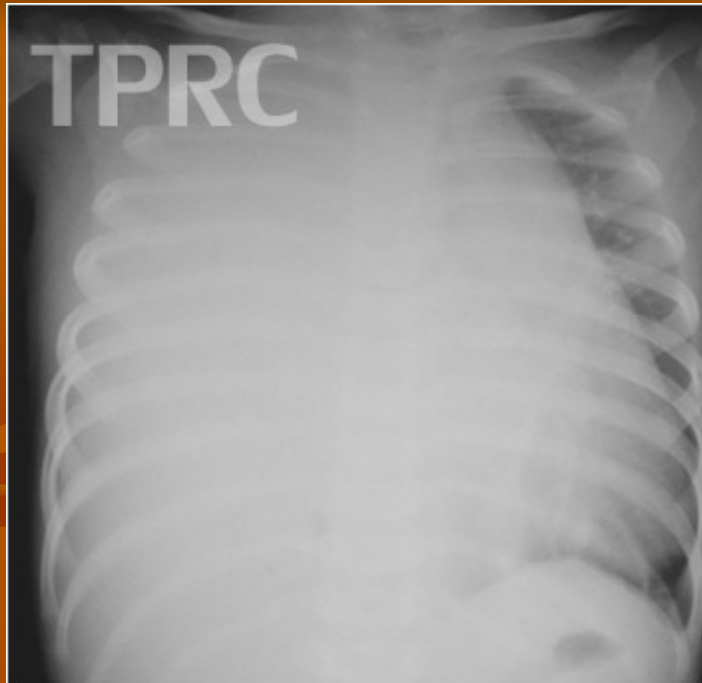No radiation

Quick

Technique

- Review the prior chest radiographs
- Transducer frequency
- Find proper window
- B-mode
- C-mode
- D-mode
- M-mode





Girl 1 year: Dyspnea and fever

Pleural tapping – some fluid

ICD placement – few blood and fluid

Film on following day

