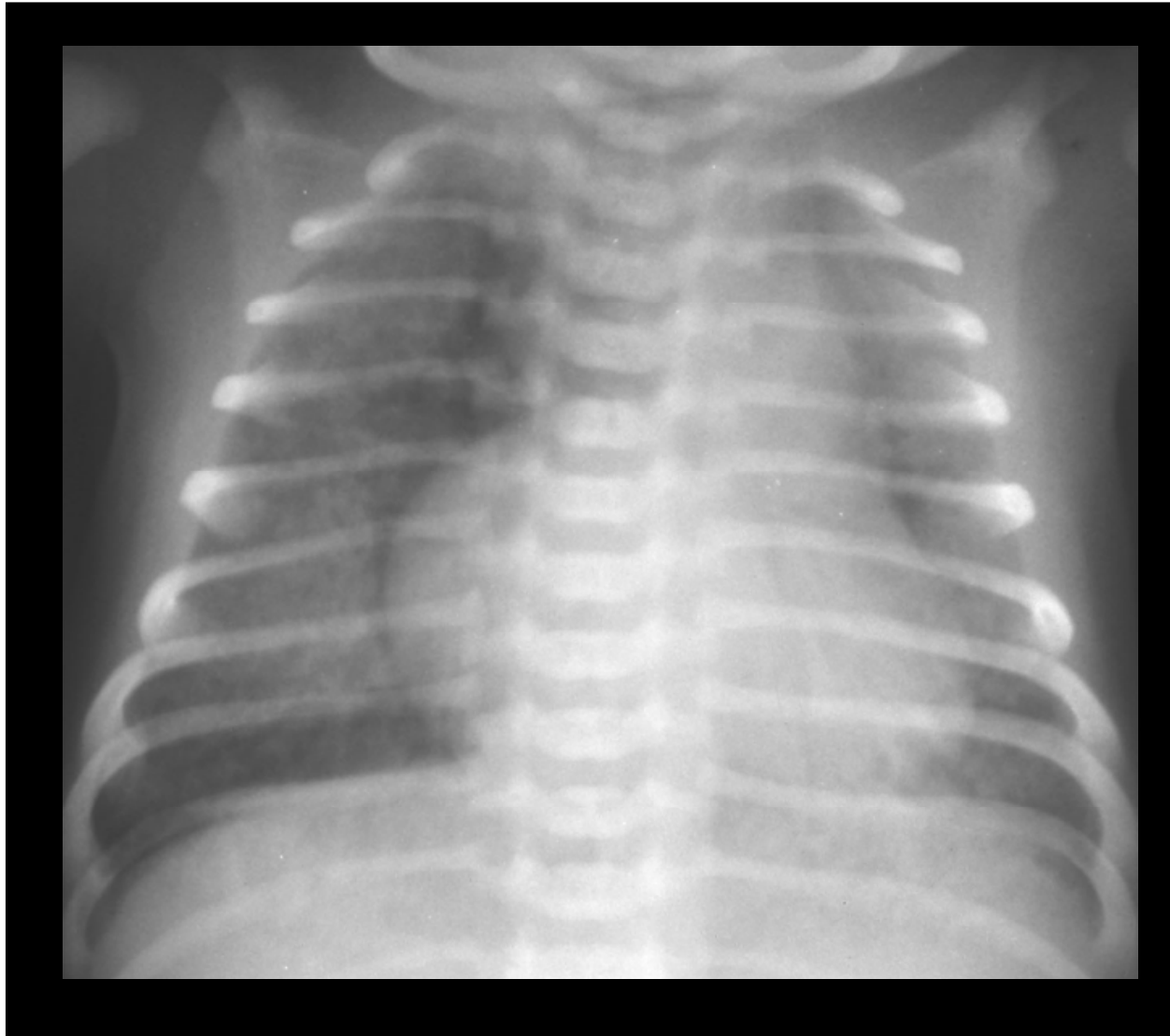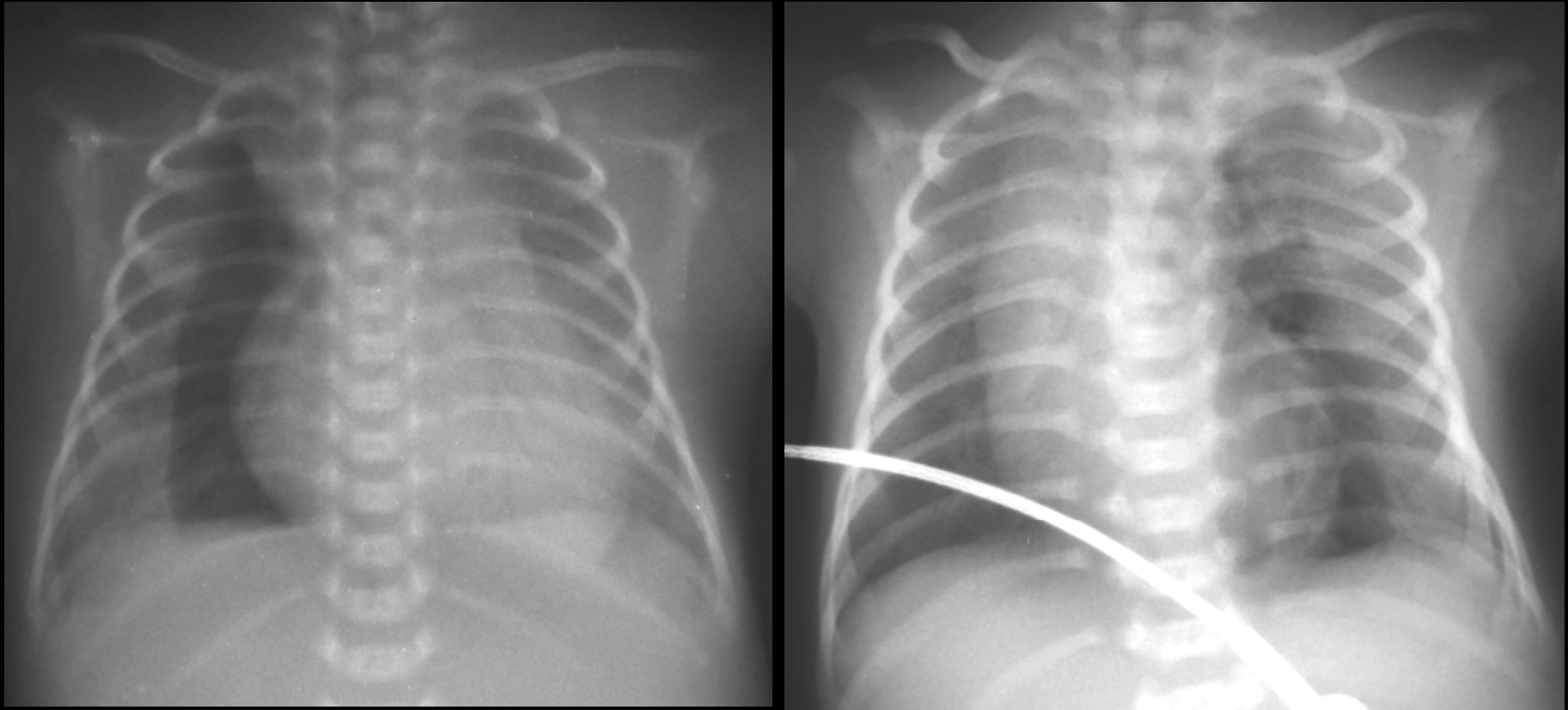


Density of the lungs
may be opaque

Chest AP supine
Boy 6 hours, MAS

**Air may be medially
located**



Medial Pneumothorax