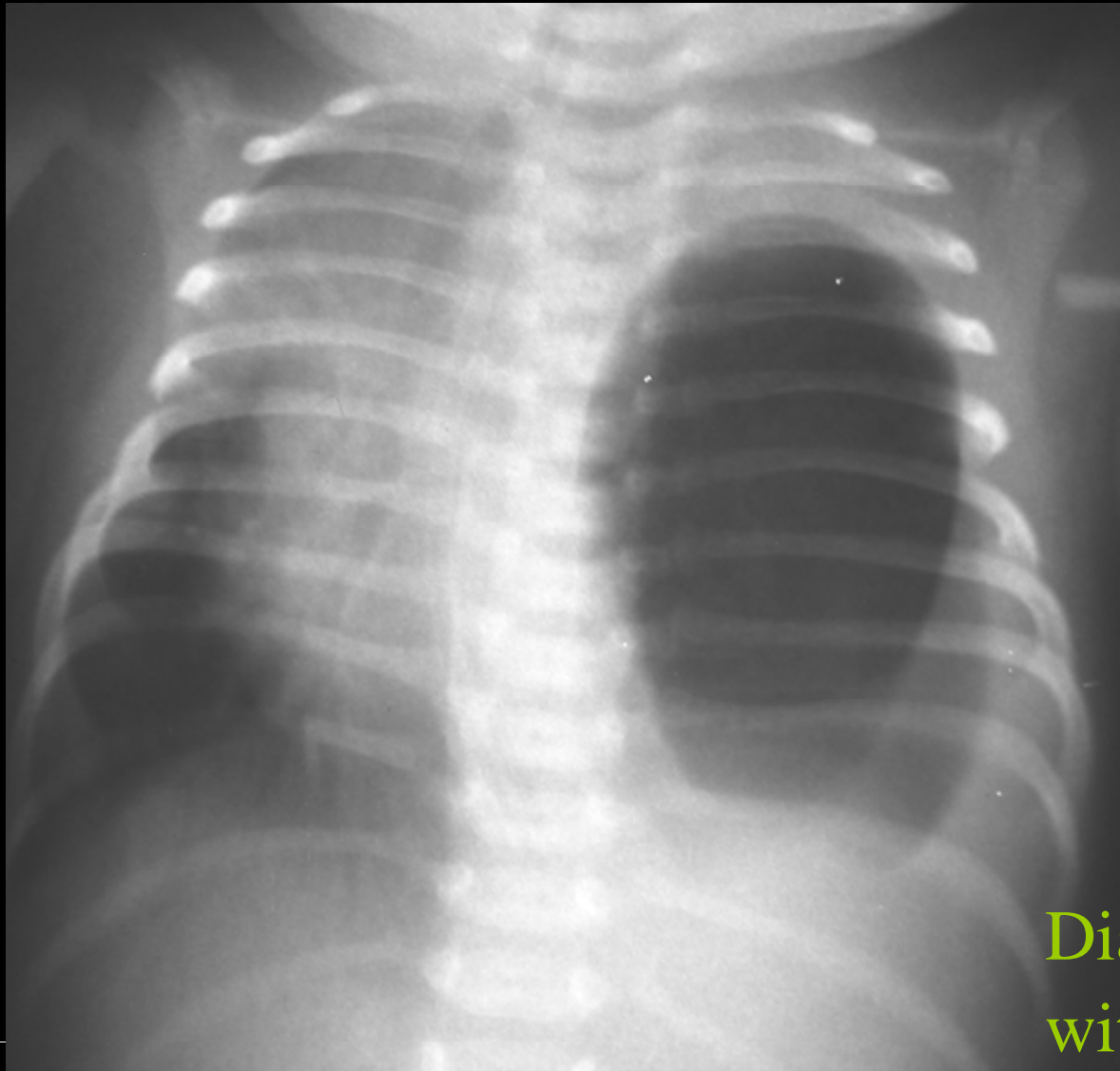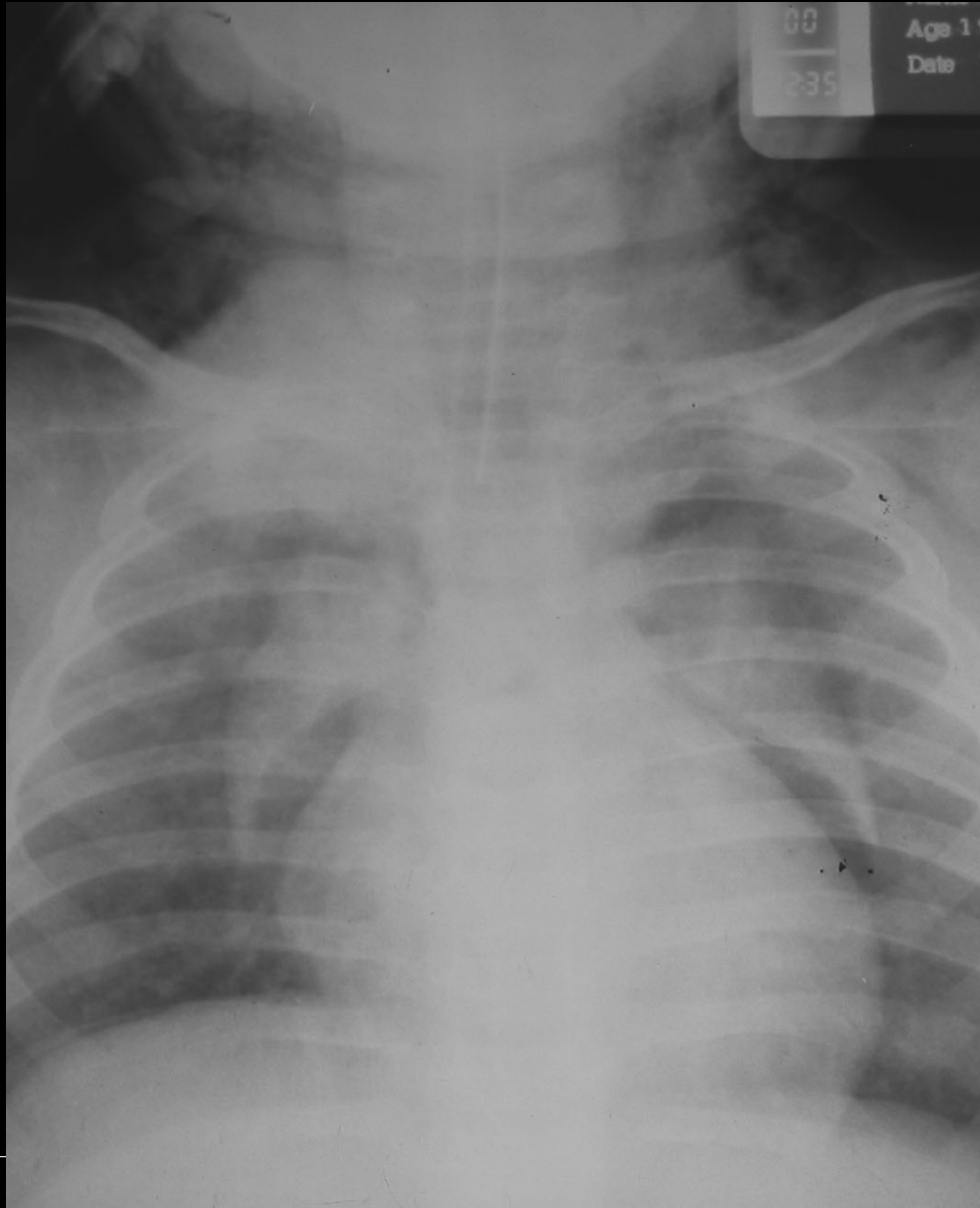


# **Lung Cyst VS Pneumothorax**

Diaphragmatic hernia  
with gastric herniation  
and volvulus



## **PNEUMO- MEDIASTINUM**

- Spinnaker sail sign **Angel wing sign**
- Subcutaneous emphysema