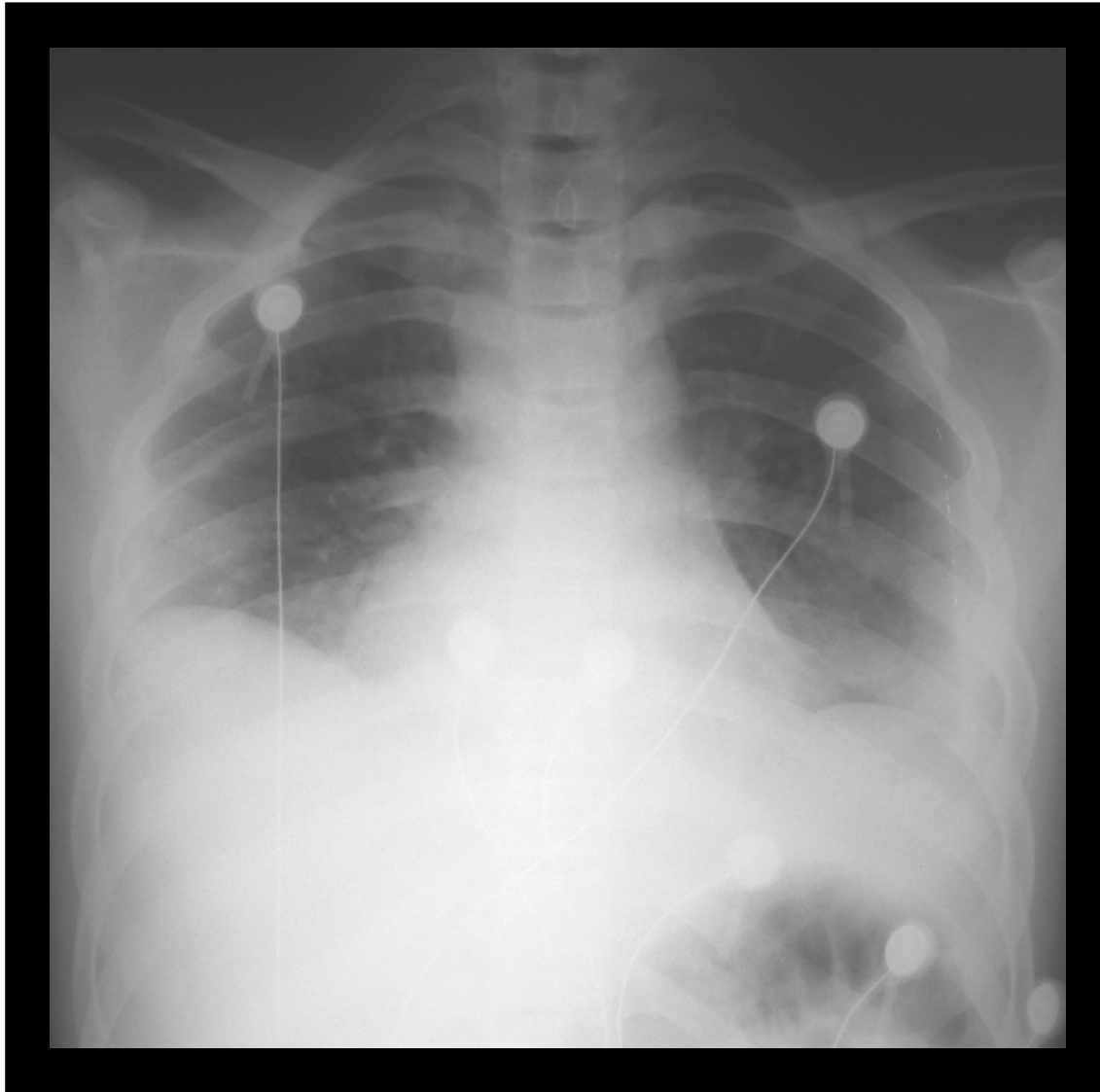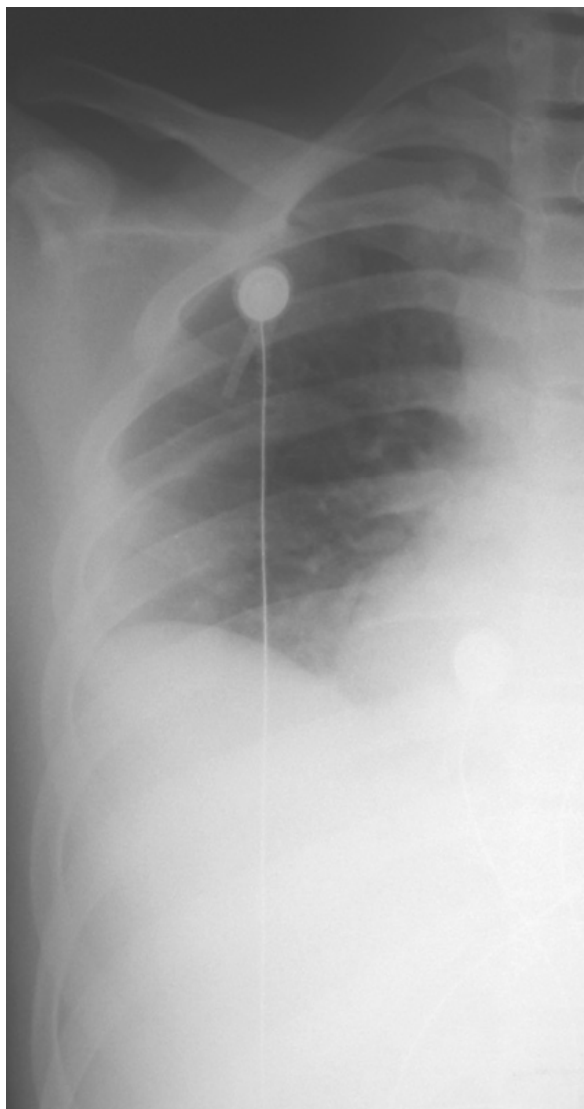


## **Subpulmonic Pleural effusion**

- Diaphragm
  - High
  - Its dome is more laterally placed

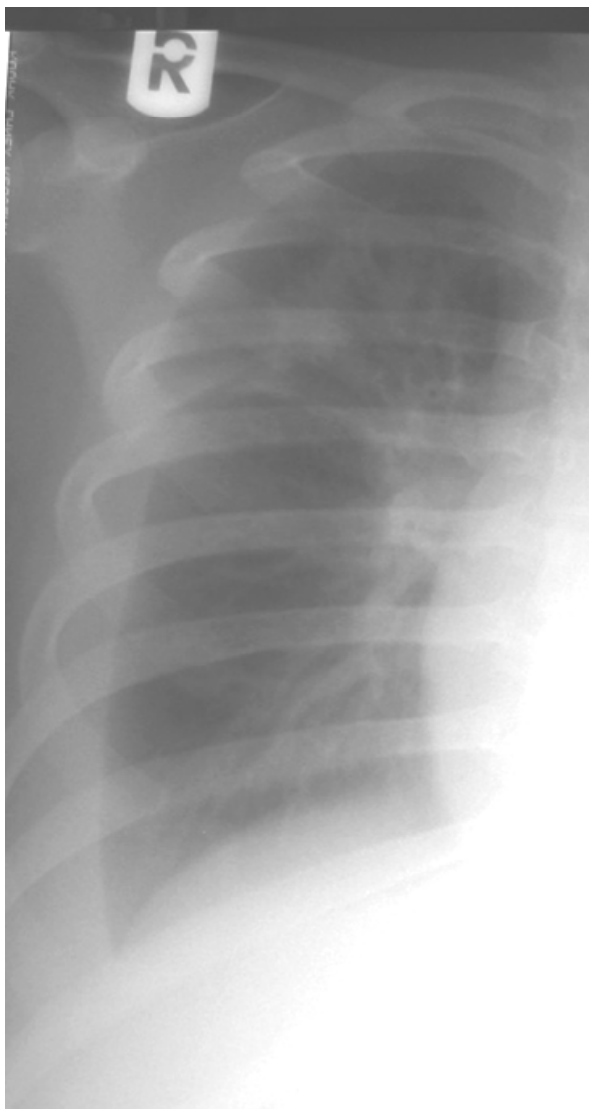
Chest PA upright

DHF

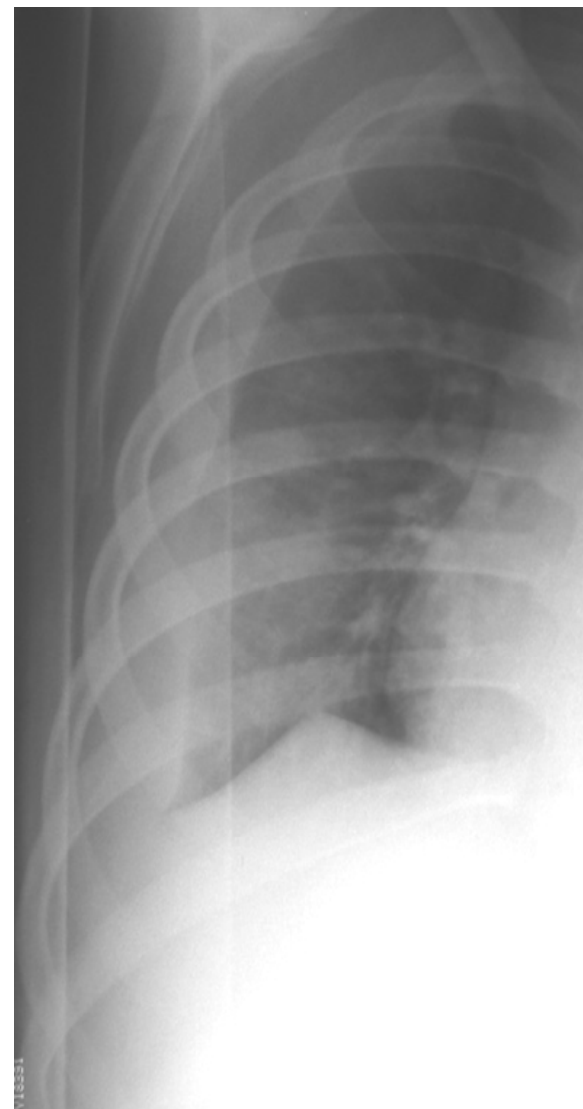

Chest PA upright

DHF



Supine



Right lateral decubitus