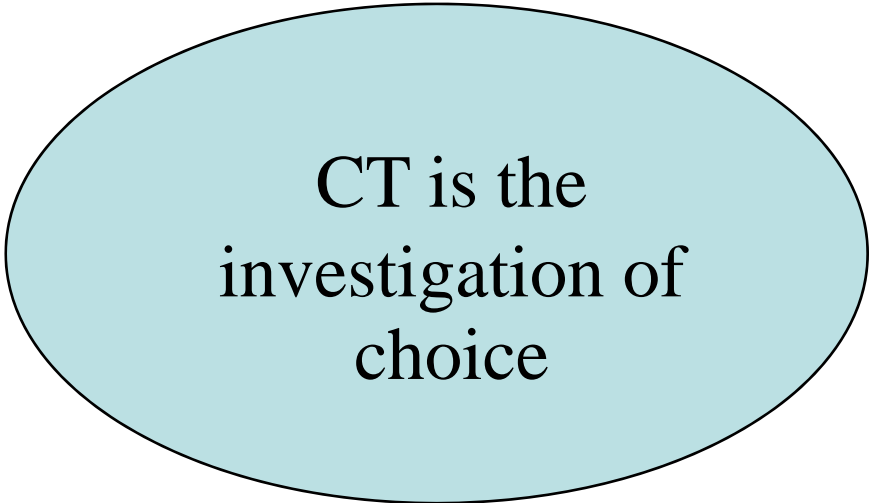
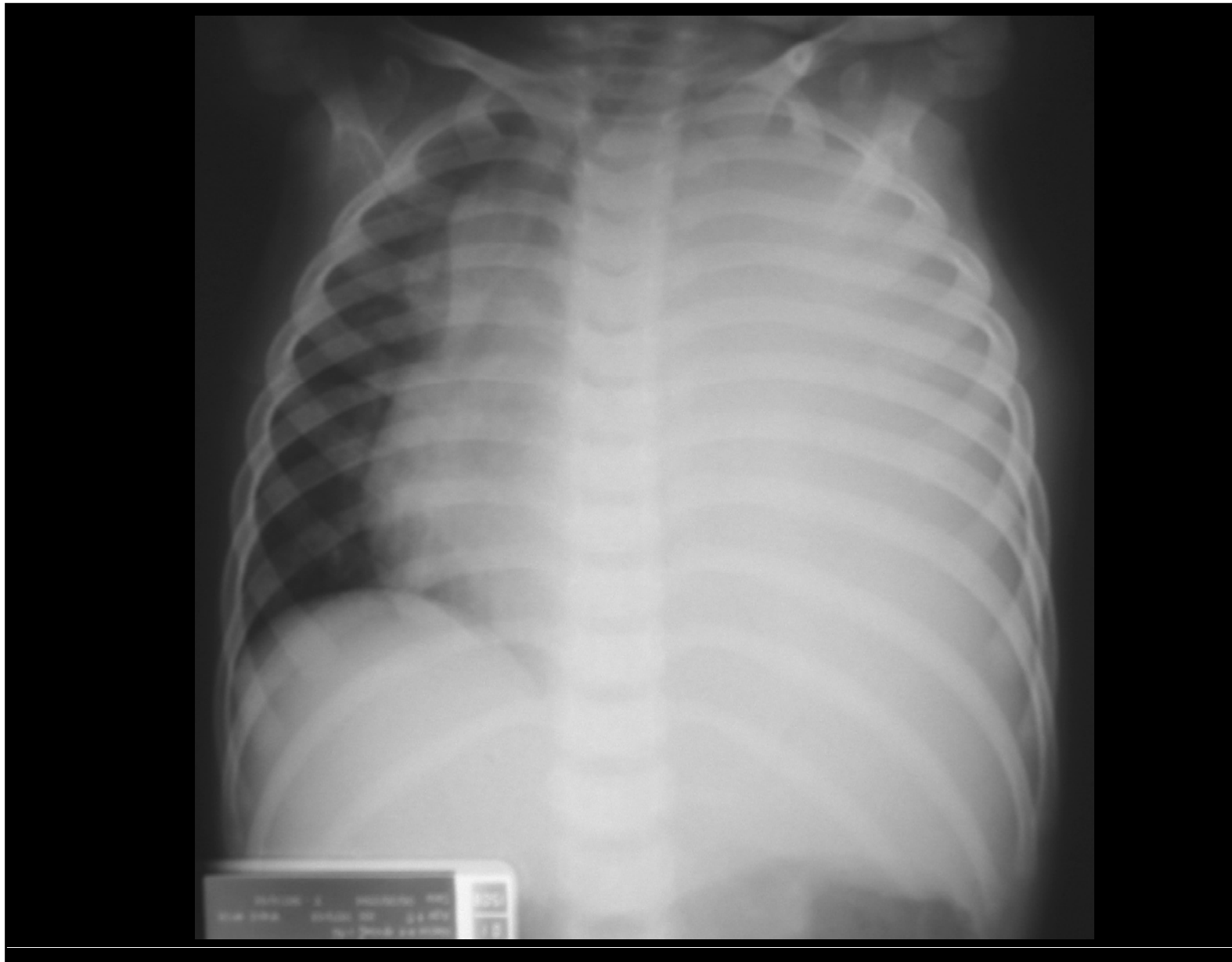


# Pleural neoplasm

- Metastasis
  - *Lymphoma*
  - *Neuroblastoma*
  - *Wilms tumor*
- Mesothelioma
- Chest wall tumor involving pleura
  - *Ewing's sarcoma / PNET*
  - *Sarcoma : Rhabdomyosarcoma*



CT is the  
investigation of  
choice



Boy 8 years, Past history of Wilms tumor