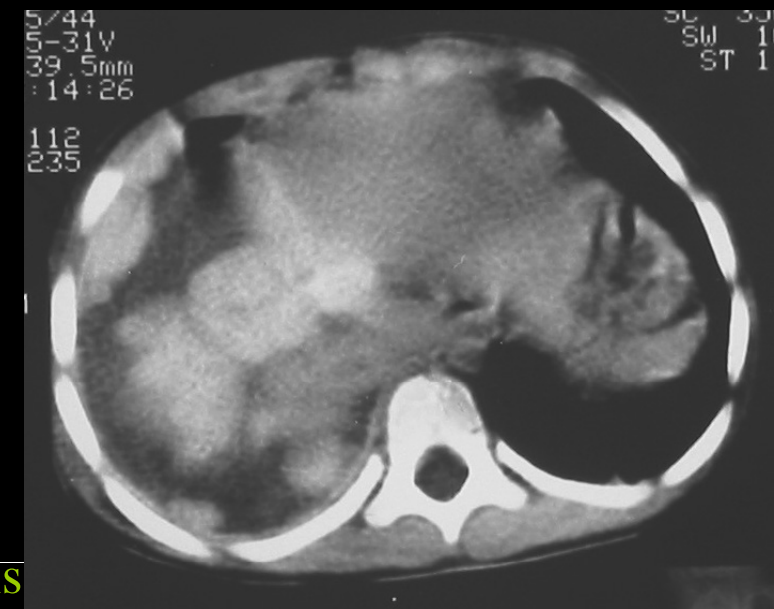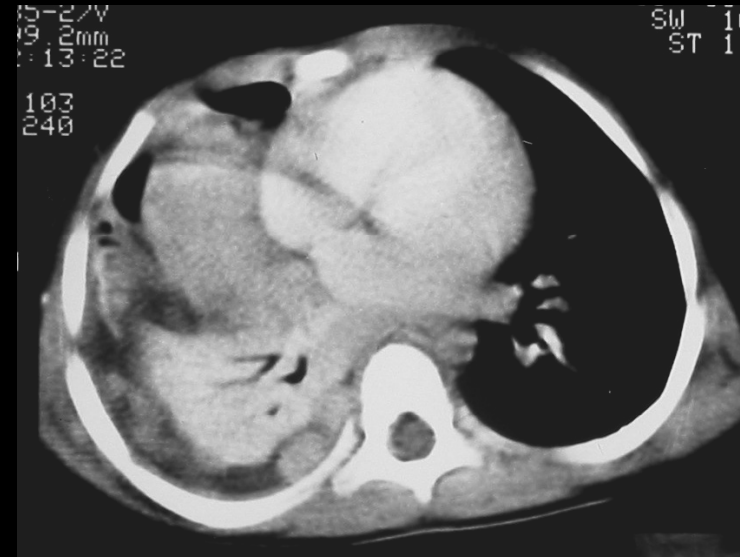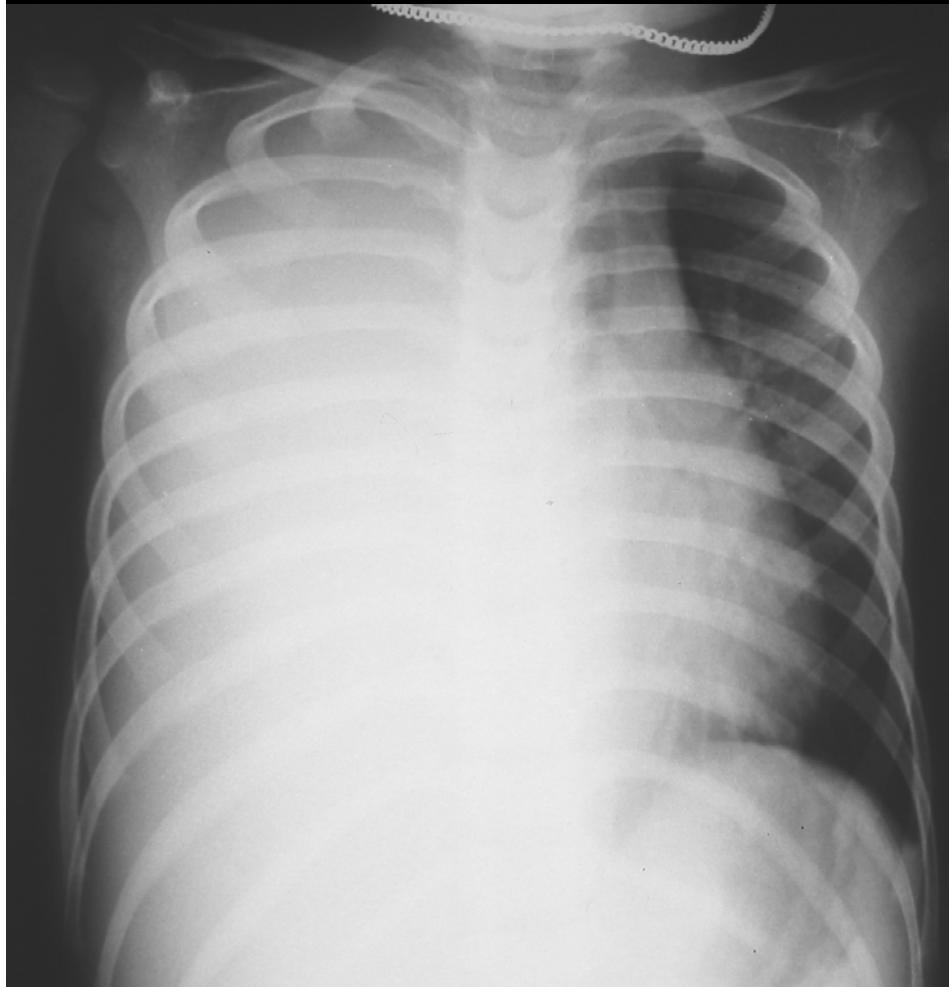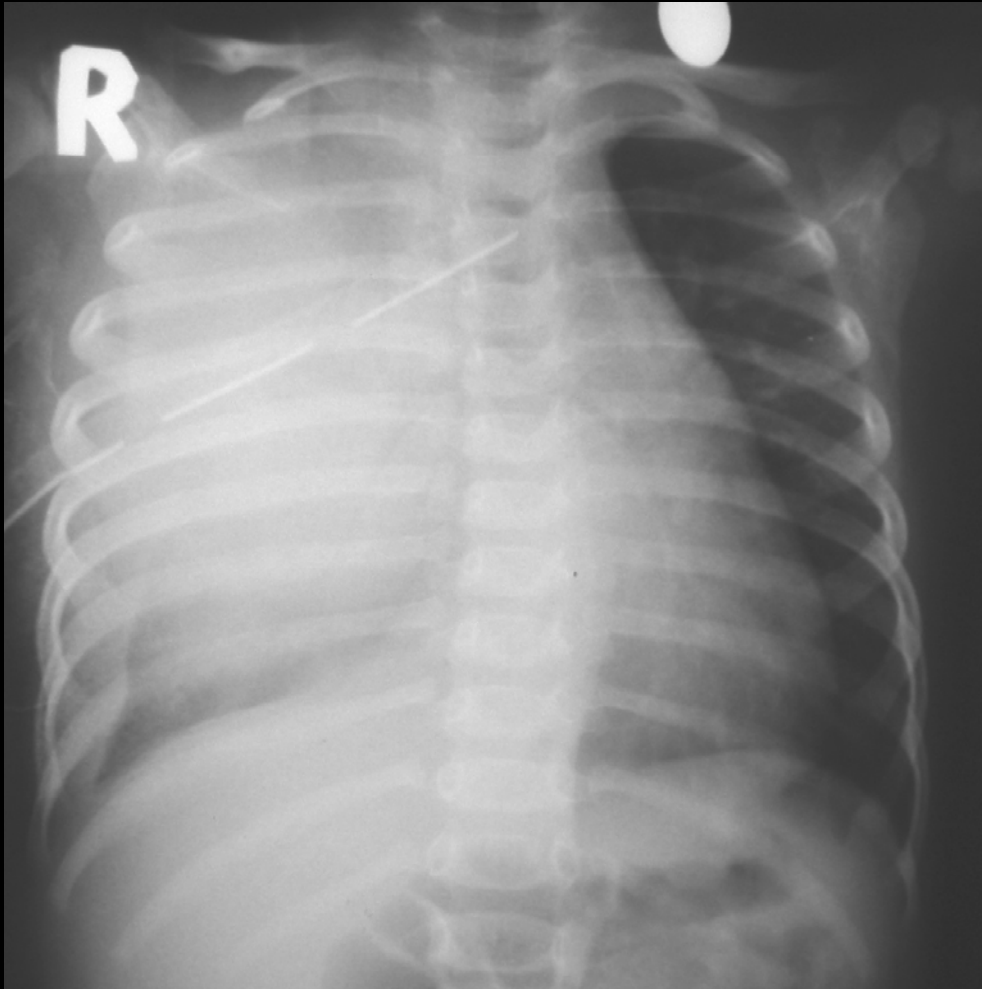


Adrenal neuroblastoma with pleural metastasis



Girl 1 year

Pleural effusion
VS
Lung mass
VS
Mediastinal
mass