



Tracheobronchial Foreign Bodies:

Diagnosis & Treatment

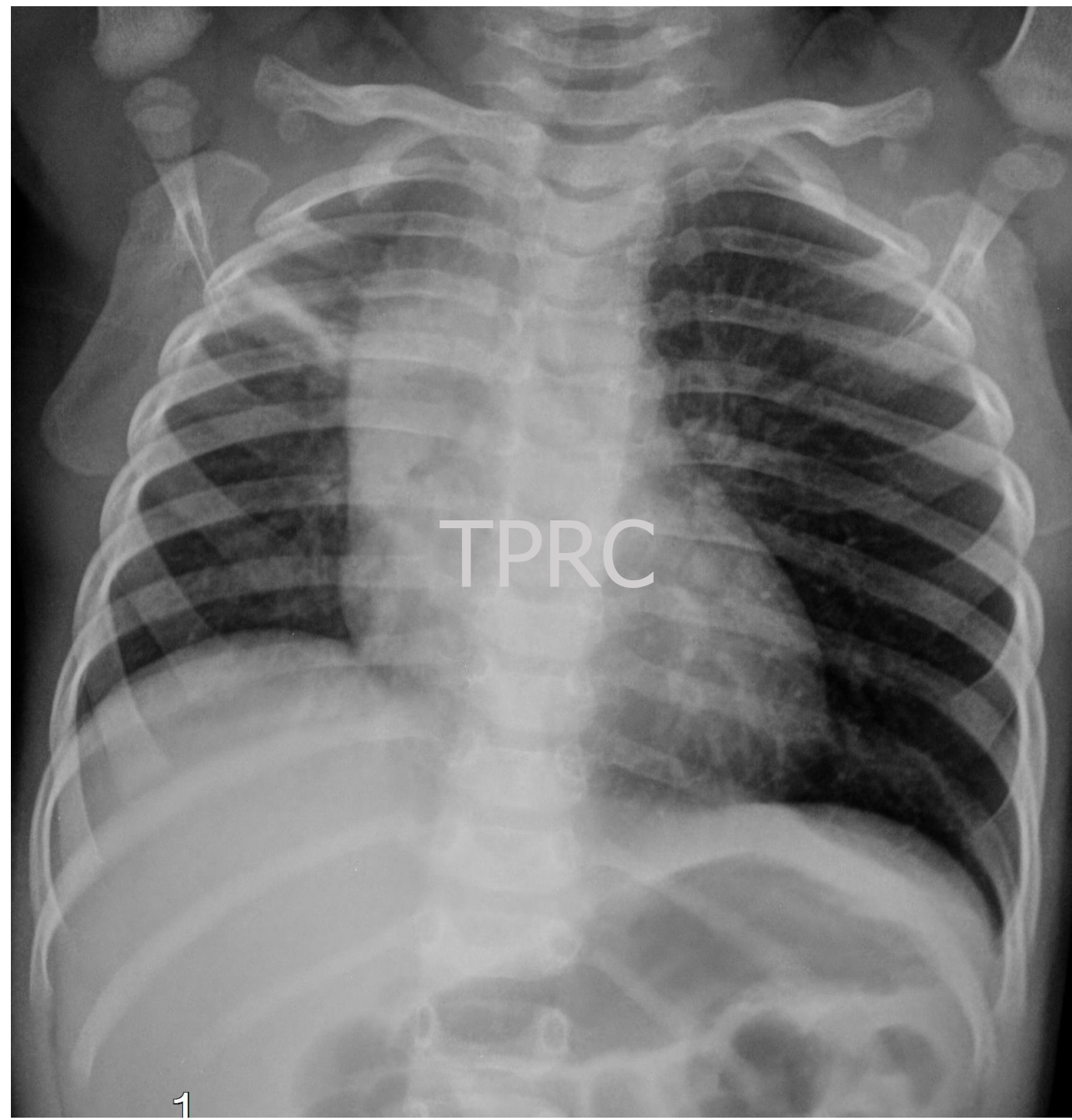
Panida Srisan, MD.

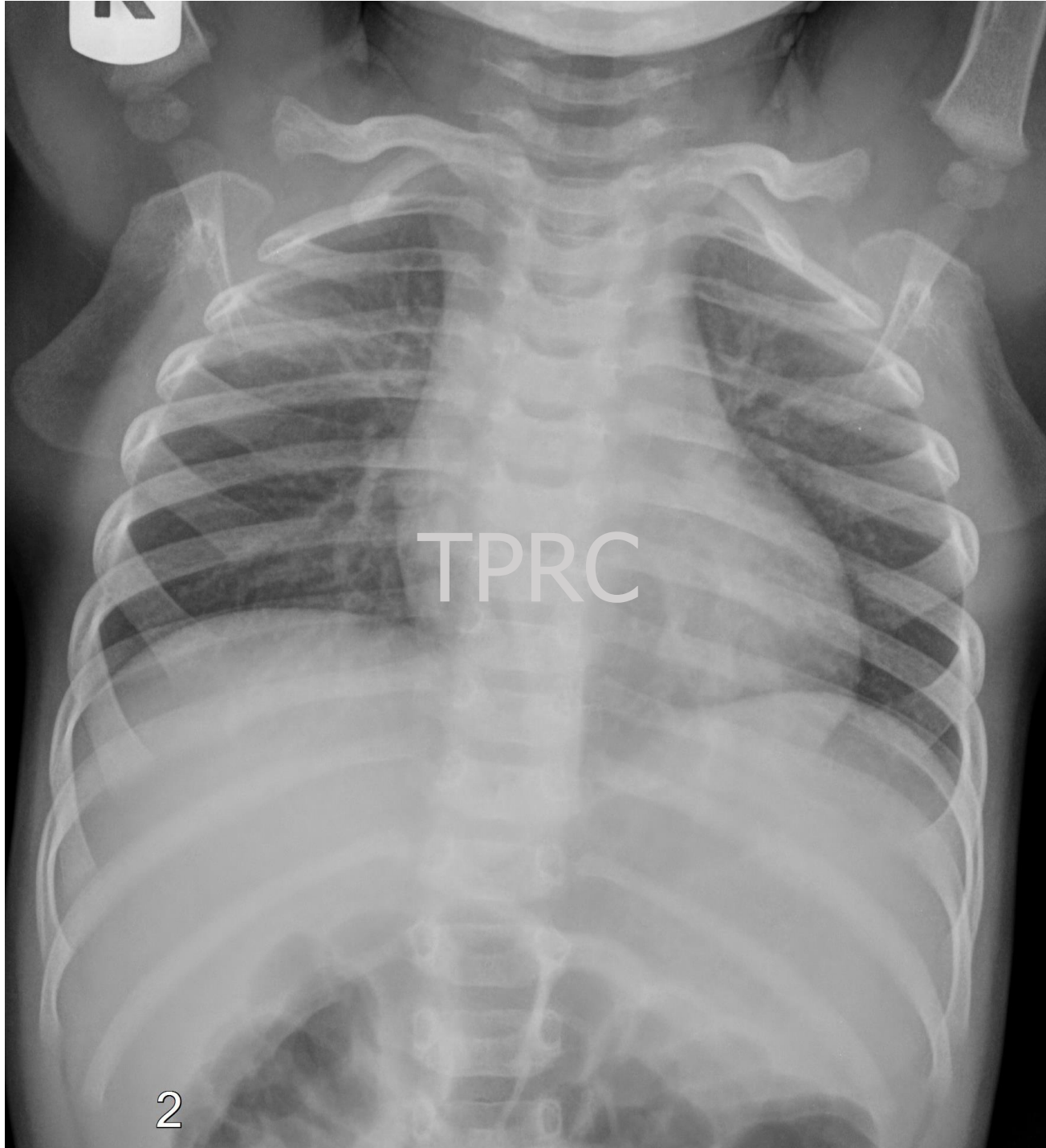
A 1 year old boy with history of choking

1 D PTA: He fell from sofa while he was eating and jumping. He developed cyanosis, aphonia and dyspnea.

At ER: central cyanosis, stuporous, poor air entry. No FB was seen during intubation.

Today: active, no dyspnea, wheezing right lung, SpO₂ 100%. He was extubated before transfer.





A 7-year-old girl with recurrent pneumonia (4 times)

01/58: RML pneumonia with pleural effusion

02/58: LLL pneumonia

07/58: LLL pneumonia

08/58: Left pleural effusion