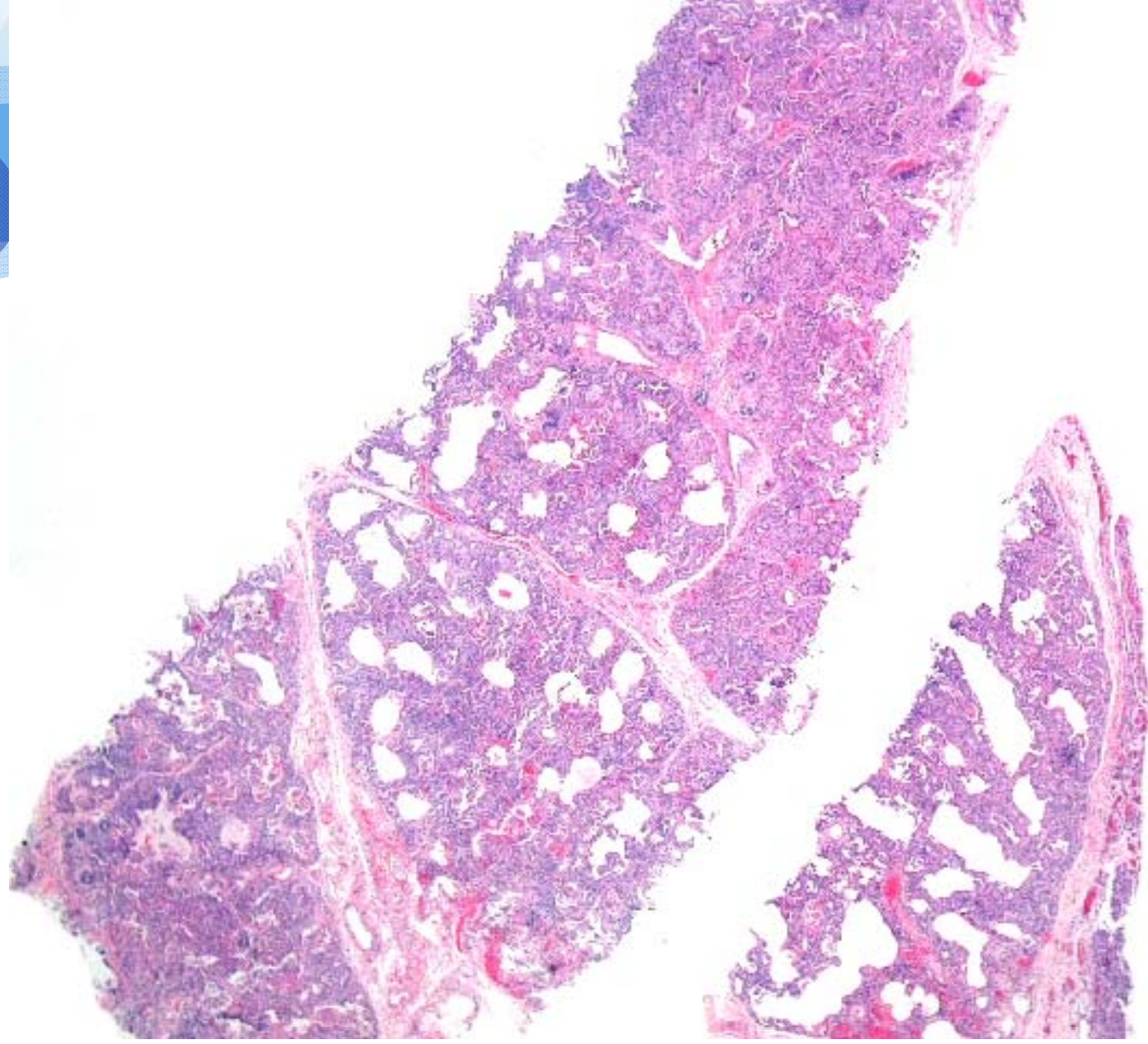


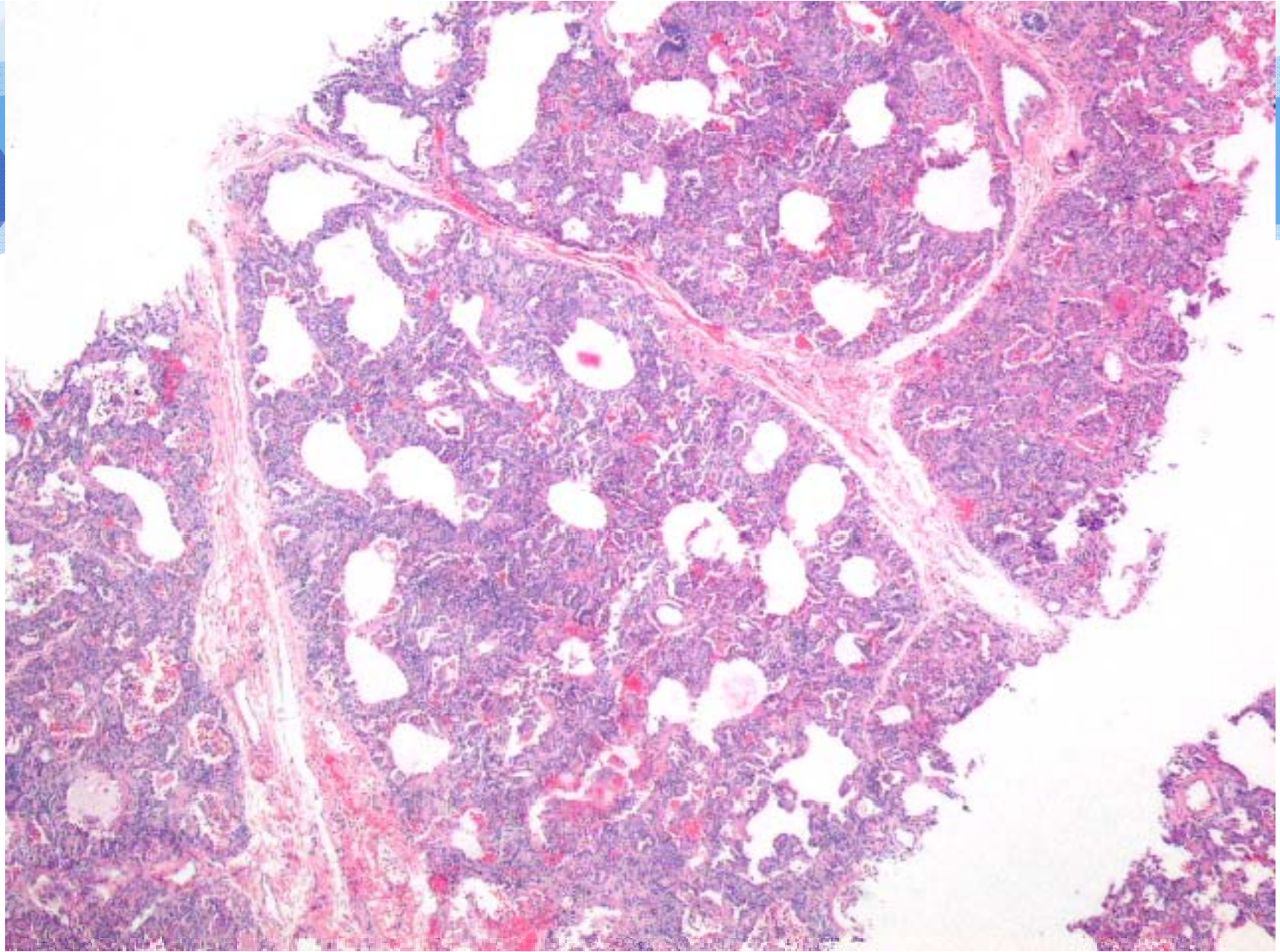
## Case 1 HN 481-27-91

- ❖ 1. S14-15886, received 25 Jun 2014
  - A: Middle lobe of the right lung (RML)
  - B: Lower lobe of the right lung (RLL)

# Microscopic morphology

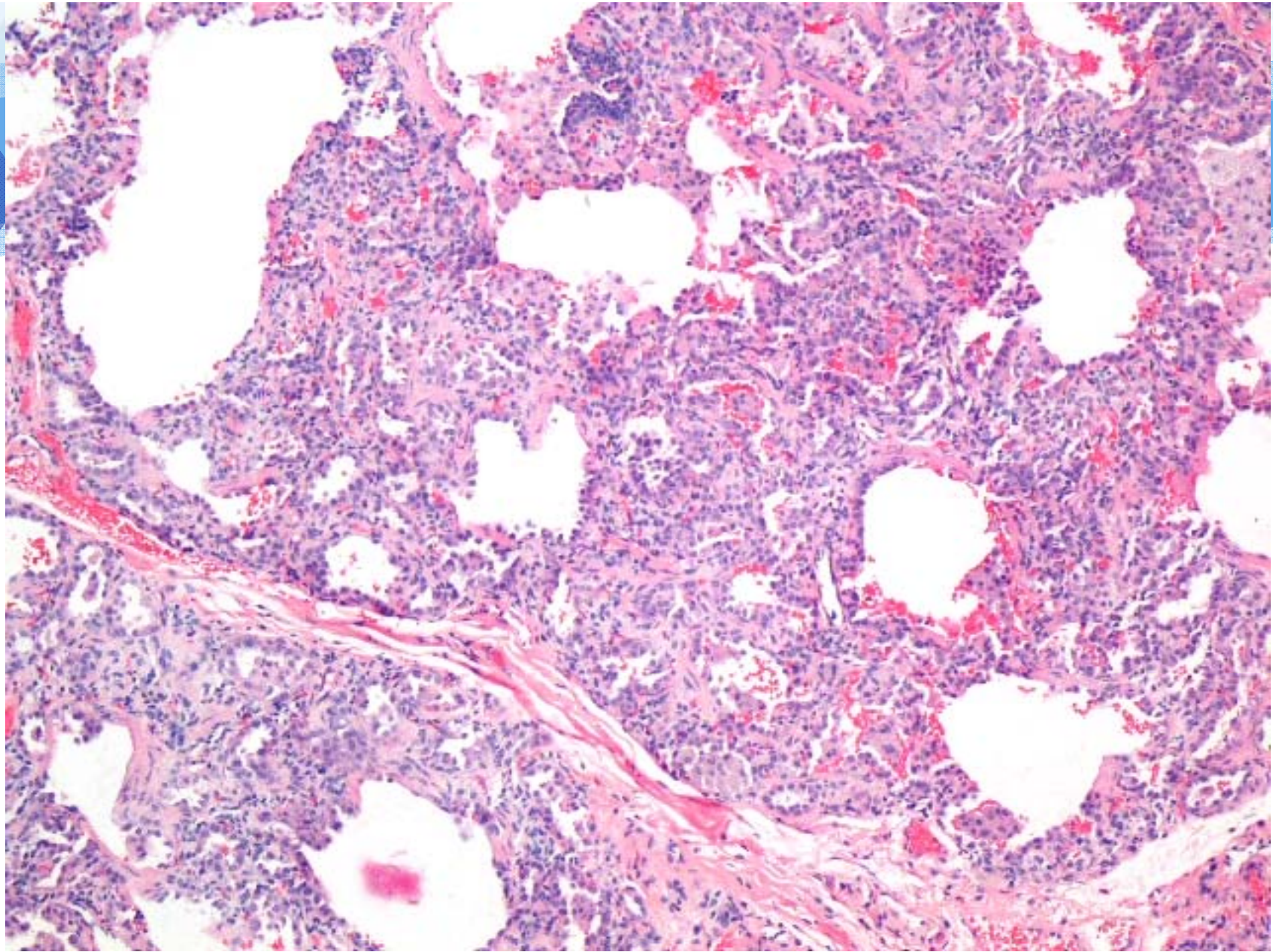


# Microscopic morphology



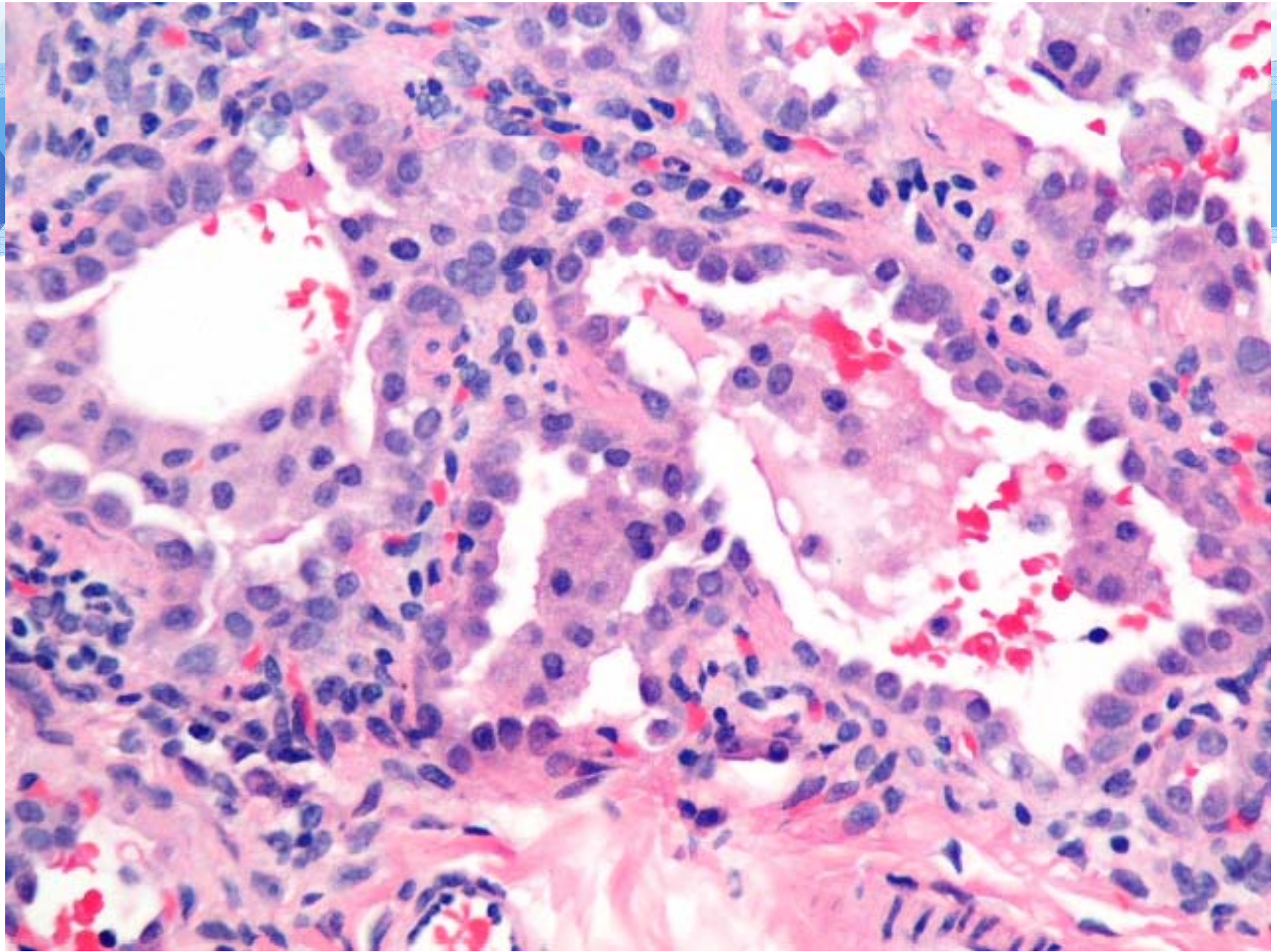
**Markedly alveolar septal thickening**

# Microscopic morphology



**Markedly alveolar septal thickening**

# Microscopic morphology



Type II pneumocyte hyperplasia